

Two Cases of Antinuclear Antibody Negative Lupus Showing Increased Proportion of B Cells Lacking RP105

SYUICHI KOARADA, MASARU IDE, YOSHIO HARUTA, YOSHIFUMI TADA, OSAMU USHIYAMA, FUMITAKA MORITO, AKIHIDE OHTA, and KOHEI NAGASAWA

ABSTRACT. B cells lacking RP105 molecule, a member of the Toll-like receptor family, were increased in the peripheral blood of 2 patients with antinuclear antibody (ANA) negative systemic lupus erythematosus (SLE). The increased proportion of RP105-lacking B cells was associated with disease activity in patients with ANA-negative SLE. When there are no significant serological markers for SLE, analysis of expression of RP105 may be helpful in evaluation of activity in ANA-negative SLE. We describe a new approach, using phenotyping of B cells, to evaluate activity of ANA-negative SLE. (J Rheumatol 2005;32:562–4)

Key Indexing Terms:

ANTINUCLEAR ANTIBODY NEGATIVE SYSTEMIC LUPUS ERYTHEMATOSUS
RP105

CD180

Systemic lupus erythematosus (SLE) is a systemic autoimmune disease characterized by multiple organ involvement with production of autoantibodies and T cell abnormalities. Antinuclear antibody (ANA) in serum is generally positive in patients with SLE, and therefore ANA-negative SLE seems to be rare¹. A clinical diagnosis of SLE can be made even though a test for ANA is negative. ANA-negative SLE seems to represent a subpopulation of SLE. We previously reported that B cells lacking RP105 molecule, a member of the Toll-like receptor family², were increased in the peripheral blood of patients with SLE^{3,4}. We describe 2 cases of ANA-negative SLE showing increased proportion of B cells lacking RP105.

CASE REPORT

Case 1. A 37-year-old man was admitted because of fever and rash. Four months earlier, a small rash had appeared on the face and extended to involve his chest and extremities. He experienced photosensitivity. He became fatigued and was admitted to our hospital. On admission, temperature was 39.5°C. He had erythematous rash on his face (malar rash). No oral ulcer was found. The lung and heart sounds were normal. There was

no evidence of active arthritis. Except for mild myalgia, the findings on neurological examination were unremarkable.

The urine was positive for protein; the sediment contained 2 to 4 red cells per high power field, with no white cells or casts. Total leukocyte count was $3.5 \times 10^9/l$, with 25% lymphocytes. Liver and renal function were normal. Complement levels were low (C3, 82 mg/dl, normal range 91–203 mg/dl; C4, 6 mg/dl, normal 13–33). Repeated evaluation showed negative tests for ANA; tests for anti-Ro and anti-La antibodies were negative, and tests for anti-dsDNA and anti-Sm antibodies were negative. ANA tests were measured by indirect immunofluorescence (IIF) performed on HEp-2 cells. Anti-Ro, anti-La, anti-dsDNA, and anti-Sm antibodies were tested by solid-phase sandwich ELISA. Radiographs of the chest showed no abnormalities. A skin biopsy from the rash showed characteristics of lupus erythematosus: perivascular and perifollicle lymphocytic infiltration in the upper dermis with vacuolar degeneration in the basal layer of the epidermis. Histology of kidney was not available.

After admission, he became confused, with disorientation and memory impairment. He became psychotic and then fell into a coma. No signs of meningeal inflammation were present. On lumbar puncture, cerebrospinal fluid (CSF) pressure was 205 mm H₂O. Protein content of the CSF was 191 mg/dl. Culture of CSF was negative. Interleukin 6 (IL-6, 192 pg/ml) and interferon- α (844 IU/ml) in CSF were elevated. Single photon emission computed tomography (SPECT) revealed hypoperfused areas in the brain except for the left frontal and parietal lobes (Figure 1). Magnetic resonance imaging examination of the brain revealed multiple areas of increased T2-weighted signal in the frontal and parietal lobes and abnormal T2 signal in thalamus. At that time tests for ANA, anti-dsDNA, and anti-ribosomal P antibodies were negative. However, anti-Sm antibody was positive (41.0 U/ml, normal < 10.0 U/ml).

The diagnosis of SLE was made based on malar rash, photosensitivity, neurological disorder, positive anti-Sm antibody, and leukocytopenia [fulfilling 5 of 11 criteria of the American College of Rheumatology (ACR) for the classification of SLE⁵]. The skin biopsy and low complement concentrations supported the diagnosis. Intravenous methylprednisolone (1000 mg/day) for 3 consecutive days was started. Two weeks later, treatment of 750 mg intravenous cyclophosphamide was added. A week later, his symptoms were improved.

Case 2. A 26-year-old man was admitted with fever, malar rash, photosen-

From the Division of Rheumatology, Saga Medical School, Saga, Japan.

Dr. Koarada is supported by grant aid for scientific research from the Ministry of Education, Science, Sports, and Culture, Japan (No.15591057).

S. Koarada, MD; M. Ide, MD; Y. Haruta, MD; O. Ushiyama, MD; F. Morito, PhD; Y. Tada, MD, Division of Rheumatology; A. Ohta, MD, Professor, Clinical Nursing; K. Nagasawa, MD, Professor, Internal Medicine, Saga Medical School.

Address reprint requests to Dr. S. Koarada, Division of Rheumatology, Saga Medical School, 5-1-1 Nabeshima, Saga, 849-8501, Japan.

E-mail: koarada@post.saga-med.ac.jp

Submitted February 5, 2004; revision accepted November 25, 2004.

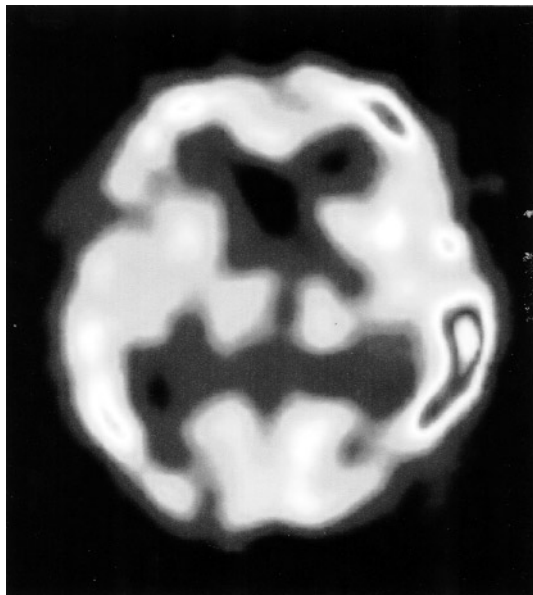


Figure 1. Single photon emission computed tomography. Case 1: Hypoperfused areas were found in the brain except for left frontal and parietal lobes.

sitivity, oral ulcers, and arthritis. Nine months before admission, he had malar rash, discoid rash and photosensitivity. Six months later, arthritis, oral ulcers, and fever appeared; he was referred from his local hospital to our hospital. On admission, urine was negative for protein; the sediment contained 1 to 2 red cells per high power field, with no casts. White blood cell count was $3.2 \times 10^9/l$ (28.5% lymphocytes). There was no liver or renal failure. Repeated serologic tests, including for ANA and antibodies to dsDNA and Sm, Ro, and La antigens, were negative. C-reactive protein was negative. Hypocomplementemia was found: C3 was 62 mg/dl; C4, 5 mg/dl. Radiographs of the chest showed no abnormalities. A skin biopsy from the rash showed characteristic features of lupus erythematosus.

Diagnosis was based on malar rash, discoid rash, photosensitivity, oral ulcers, arthritis, and leukocytopenia and fulfilled 6 of 11 ACR criteria for SLE. He was treated with prednisolone (30 mg/day), which resulted in rapid resolution of his symptoms and a good response.

Patients' blood samples were evaluated in this study. Peripheral blood mononuclear cells (PBMC) were separated by Ficoll-Paque (Pharmacia Biotech, Uppsala, Sweden) after centrifugation. Cell suspensions in staining buffer (phosphate buffered saline supplemented with 2.0% fetal calf serum) were incubated with FITC conjugated anti-human CD19 monoclonal antibody (PharMingen, San Diego, CA, USA) and phycoerythrin conjugated anti-human RP105 mAb (PharMingen) for 20 min. Labeled cells were analyzed using FACScan (Becton Dickinson, Mountain View, CA, USA). List mode data were collected and analyzed using WinMDI (v. 2.8) software written by J. Trotter (<http://facs.scripps.edu/software.html>). The expression of RP105 on B cells was analyzed. B cells lacking RP105 were 21.0% in Case 1 and 44.0 % in Case 2 (Figure 2). Serial analyses of patients' peripheral blood after treatment revealed that RP105-lacking B cells had decreased (7.3% in Case 1 and 3.4% in Case 2) in parallel with a reduction in disease activity; SLE Disease Activity Index scores decreased from 29 to 3 in Case 1 and from 12 to 2 in Case 2.

DISCUSSION

In 1981, Maddison, *et al* described patients who had the clinical findings of SLE but who were ANA-negative¹. These cases were designated ANA-negative SLE; many similar cases have been reported to date⁶⁻¹³. We describe 2 cases of ANA-negative SLE who had increased proportion of RP105-lacking B cells. Our findings provide a new approach, using phenotyping of B cells, to evaluate the disease activity of patients with ANA-negative SLE.

RP105 is a member of the Toll-like receptor family, a cell surface molecule on B cells that induces proliferation and resistance against radiation induced apoptosis upon ligation by antibodies to RP105¹⁴. Previously, we reported that an increased proportion of RP105-lacking B cells was found in patients with SLE³. The functional role of RP105-lacking B cells in SLE has been reported¹⁵. RP105-lacking B cells from patients with SLE produce IgG and IgM antibodies *in vitro*. Moreover, spontaneous IgG and IgM antibodies from RP105-lacking B cells *in vitro* were enhanced by exposure to *Staphylococcus aureus* Cowan I (SAC) or IL-6. Interestingly, in cultures with activated T cells, RP105-lack-

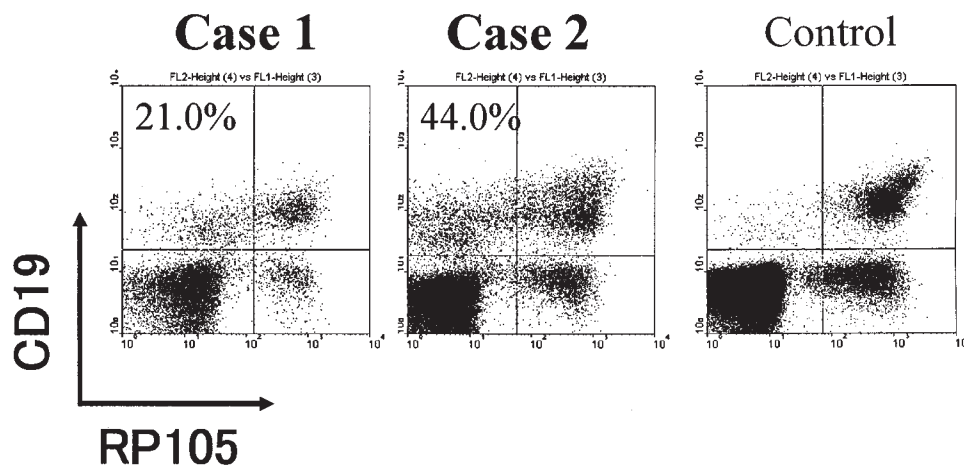


Figure 2. FACS profiles of PBMC stained with FITC-anti-CD19 and phycoerythrin-anti-RP105 antibodies from patients with ANA-negative SLE (left panels) and a healthy control (right panel).

ing B cells produced anti-dsDNA antibodies that were specific for SLE¹⁵. As well, we reported that an increased proportion of RP105-lacking B cells was also found in patients with Sjögren's syndrome and dermatomyositis^{4,16}, which are known to be characterized by B cell hyperactivation. RP105-lacking B cells may include the subsets of autoreactive B cells found in autoimmune diseases.

This assay plays a role in evaluation of activity of SLE with high sensitivity. The presence of increased RP105-lacking B cells suggested polyclonal B cell hyperactivation and hypergammaglobulinemia. However, in our 2 cases, serum IgG concentrations were within normal ranges. Our 2 cases showed increased proportions of RP105-lacking B cells and negative tests for ANA. Therefore, the assay for RP105-lacking B cells may have been more sensitive than serum IgG levels and ANA in our 2 cases. In our preliminary study, the presence of increased RP105-lacking B cells was uncommon in inflammatory or infectious diseases including tuberculosis and chronic hepatitis C virus infection. However, the precise specificity and sensitivity of the assay for RP105-lacking B cells in the diagnosis of SLE remains an important issue.

Our cases were both men, which is unusual in SLE; it will be necessary to accumulate cases and investigate further the correlation of RP105-lacking B cells and ANA-negative SLE. Our Case 1 showed positive anti-Sm antibody in the active phase of the disease. In general, positive anti-Sm and anti-dsDNA antibody tests are not consistent with negative tests for ANA. However, Morris, *et al* have reported a positive test for anti-dsDNA antibody in ANA-negative SLE¹¹. Another report described positive anti-DNA antibodies without ANA in sera from SLE patients¹⁷. Moreover, Sugisaki, *et al* observed antiribosomal P antibody in ANA-negative SLE⁷. As well, a high prevalence of anti-Ro antibody and anti-La antibody has been reported in patients with ANA-negative SLE⁸. Again, we have to accumulate cases and further investigate serological findings of positive anti-Sm antibody even in cases of ANA-negative SLE.

We describe 2 patients with ANA-negative SLE showing increased concentrations of B cells lacking RP105. An increased proportion of RP105-lacking B cells is associated with disease activity even in patients with ANA-negative SLE. Analysis of expression of RP105 on B cells may be a sensitive method of evaluation of activity in patients with ANA-negative SLE; however, its significance in diagnosis is still open to debate.

ACKNOWLEDGMENT

We thank Motoko Fujisaki for help in the description of the disease course.

REFERENCES

1. Maddison PJ, Provost TT, Reichlin M. Serological findings in patients with "ANA-negative" systemic lupus erythematosus. *Medicine* 1981;60:87-94.
2. Miyake K, Ogata H, Nagai Y, Akashi S, Kimoto M. Innate recognition of lipopolysaccharide by Toll-like receptor 4/MD-2 and RP105/MD-1. *J Endotoxin Res* 2000;6:389-91.
3. Koarada S, Tada Y, Ushiyama O, et al. B cells lacking RP105, a novel B cell antigen, in systemic lupus erythematosus. *Arthritis Rheum* 1999;42:2593-600.
4. Koarada S, Tada Y, Kikuchi Y, et al. CD180 (RP105) in rheumatic diseases. *Rheumatology Oxford* 2001;40:1315-6.
5. Tan EM, Cohen AS, Fries JF, et al. The 1982 American College of Rheumatology revised criteria for the classification of systemic lupus erythematosus. *Arthritis Rheum* 1982;25:1271-7.
6. Maraina CH, Kamaliah MD, Ishak M. ANA negative (Ro) lupus erythematosus with multiple major organ involvement: a case report. *Asian Pac J Allergy Immunol* 2002;20:279-82.
7. Sugisaki K, Takeda I, Kanno T, et al. An anti-nuclear antibody-negative patient with systemic lupus erythematosus accompanied with anti-ribosomal P antibody. *Intern Med* 2002;41:1047-51.
8. Reichlin M. ANA negative systemic lupus erythematosus sera revisited serologically. *Lupus* 2000;9:116-9.
9. Khajehdehi P, Islam SF, Salinas-Madrigal L, Bastani B. Lupus nephritis in an anti-nuclear antibody-negative young male. The simultaneous presence of class III and class V renal lesions. *Clin Nephrol* 1999;51:379-82.
10. Zoli A, Altomonte L, Galossi A, Taranto A, Mirone L, Magaro M. Neurobehavioural and psychiatric manifestations in a case of ANA-negative SLE with antiphospholipid antibodies. *Clin Rheumatol* 1998;17:68-70.
11. Morris CN, Calobrisi SD, Matteson EL. Antinuclear antibody negative lupus associated with dystrophic calcification. *J Rheumatol* 1998;25:825-6.
12. Blaustein DA, Blaustein SA. Antinuclear antibody negative systemic lupus erythematosus presenting as bilateral facial paralysis. *J Rheumatol* 1998;25:798-800.
13. Sircar S, Taneja VA, Kansra U. ANA-negative SLE presenting with nephritis and oculomotor palsy — a case report. *Indian J Pathol Microbiol* 1997;40:539-42.
14. Kimoto M, Nagasawa K, Miyake K. Role of TLR4/MD-2 and RP105/MD-1 in innate recognition of lipopolysaccharide. *Scand J Infect Dis* 2003;35:568-72.
15. Kikuchi Y, Koarada S, Tada Y, et al. RP105-lacking B cells from lupus patients are responsible for the production of immunoglobulins and autoantibodies. *Arthritis Rheum* 2002;46:3259-65.
16. Kikuchi Y, Koarada S, Tada Y, et al. Difference in B cell activation between dermatomyositis and polymyositis: analysis of the expression of RP105 on peripheral blood B cells. *Ann Rheum Dis* 2001;60:1137-40.
17. McHardy KC, Horne CH, Rennie J. Antinuclear antibody-negative systemic lupus erythematosus — how common? *J Clin Pathol* 1982;35:1118-21.