

Case Report

Kaposi's Sarcoma Following Immune Suppressive Therapy for Wegener's Granulomatosis

ISABELLE DESCHÊNES, LOUISE DION, CLAUDE BEAUCHESNE, and ARTUR J. de BRUM-FERNANDES

ABSTRACT. The association between Kaposi's sarcoma and infection with human herpesvirus 8 is now well recognized. Immunologic impairment is associated with 2 forms of Kaposi's sarcoma, epidemic [associated with human immunodeficiency virus (HIV) infection] and iatrogenic (associated with immunosuppressive treatment); both forms have become more common during the last decade. We describe an HIV negative 54-year-old man who developed Kaposi's sarcoma 2 months after the beginning of immunosuppressive therapy for Wegener's granulomatosis (WG). With tapering of medication, complete remission of Kaposi's sarcoma was achieved in one year. To our knowledge, this is the second reported case of iatrogenic Kaposi's sarcoma in a patient with WG. (*J Rheumatol* 2003;30:622-4)

*Key Indexing Terms:*WEGENER'S GRANULOMATOSIS
CORTICOSTEROIDSKAPOSI'S SARCOMA
IMMUNOSUPPRESSION

Kaposi's sarcoma (KS) is a multisystemic vascular neoplasia currently divided in 4 clinical variants: classic, endemic, epidemic [associated with human immunodeficiency virus (HIV) infection], and iatrogenic (associated with immunosuppressive treatment)¹. These variants differ in their epidemiology, clinical presentation, and evolution rather than in their pathologic diagnosis^{1,2}. The link between KS and human herpesvirus 8 (HHV-8), also called Kaposi's sarcoma associated herpesvirus, has been known since 1994²⁻⁴. Modes of transmission of HHV-8 are not all clearly defined. Sexual transmission is well established and homosexual men are at higher risk to be infected and to develop KS, independently of HIV co-infection^{2,4}. Vertical transmission is more prevalent in endemic regions, either at birth or via the placenta. Organ recipients have shown seroconversion after transplant from an infected donor. The virus is frequently present in the saliva of infected persons. Whether HHV-8 can be transmitted via saliva or blood products is unknown².

CASE REPORT

The patient was a 54-year-old Caucasian bisexual man, previously in good health, who presented in November 1998 with hemoptysis and a 3 month history of sinusitis. A computed tomography scan of the sinus and lungs revealed bilateral sphenoidal sinusitis and pulmonary cavitory lesions with hilar adenopathies. Laboratory tests showed the following results: cytoplasmic

antineutrophil cytoplasmic antibody (cANCA) positive 1/160, anti-proteinase-3 positive (ELISA), and anti-myeloperoxidase negative. Left nasal septum biopsy revealed severe necrotizing inflammation with giant multinucleated cells compatible with Wegener's granulomatosis (WG). He received intravenous methylprednisolone for 3 days (1 g/day) and left the hospital taking prednisone (80 mg/day) and cyclophosphamide (150 mg/day). In December 1998, he was hospitalized for a pulmonary abscess and secondary *Staphylococcus aureus* septicemia. He was treated with cloxacillin for 6 weeks and left the hospital taking prednisone 50 mg/day and cyclophosphamide 100 mg/day. In January 1999, he was treated for a parotitis with amoxicillin-clavulanate and then trimethoprim-sulfamethoxazole for 14 days. He also reported cutaneous lesions over the trunk, arms, back, and legs that rapidly evolved since the end of December 1998 (Figure 1). Examination showed maculopapular and nodular violaceous, unpainful lesions on the trunk, arms, and legs. A skin biopsy revealed a vascular neoplasia with spindle endothelial cells and atypical nuclei (Figure 2). The pathologic diagnosis was KS. Cyclophosphamide was reduced to 50 mg/day. Trimethoprim-sulfamethoxazole was continued on a regular basis as an adjunct treatment for WG.

In March 1999 he was hospitalized for a manic episode associated with prednisone. Maculopapular and nodular violaceous lesions were present over the arms, legs, and trunk, but not on the face, mouth, or genitals. The chest radiograph only showed known cicatricial lesions. Lymphocyte subsets were quantified by flow cytometry. Total CD3 positive T cells were 167/mm³ (normal range 935-3560/mm³). CD4 positive were 69/mm³ (normal 725-2220) and CD8 positive were 92/mm³ (normal 300-1440). HIV enzyme immunoassay (EIA) serologic test and p24 antigenemia (EIA) were negative and the viral load was less than 50 copies per milliliter of plasma. The cANCA was negative and prednisone was reduced over one month to 10 mg/day.

From April 1999 to January 2000, there was progressive disappearance of the cutaneous lesions. Prednisone was stopped in January 2000. In April 2000, there were only cicatricial cutaneous lesions and trimethoprim-sulfamethoxazole was ceased. Cyclophosphamide was stopped in November 2000.

In December 2001, there was no evidence of active WG clinically, radiologically, or in laboratory tests. Cutaneous lesions had not recurred and the HIV serology remained negative. The lymphocyte cell count was normal.

DISCUSSION

KS is a frequent opportunistic tumor among persons who have risk factors for HHV-8 infection, such as homosexual men,

From the Division of Rheumatology, Division of Infectious Diseases, and Division of Pathology, Faculty of Medicine, Université de Sherbrooke, Sherbrooke, Quebec, Canada.

I. Deschênes, MD; L. Dion, MD; C. Beauchesne, MD; A.J. de Brum-Fernandes, MD, PhD.

Address reprint requests to Dr. A.J. de Brum-Fernandes, Centre Hospitalier Universitaire de Sherbrooke, Service de Rhumatologie, 3001 12e Avenue Nord, Fleurimont, Québec J1H 5N4, Canada.

Submitted January 10, 2002; revision accepted August 28, 2002.

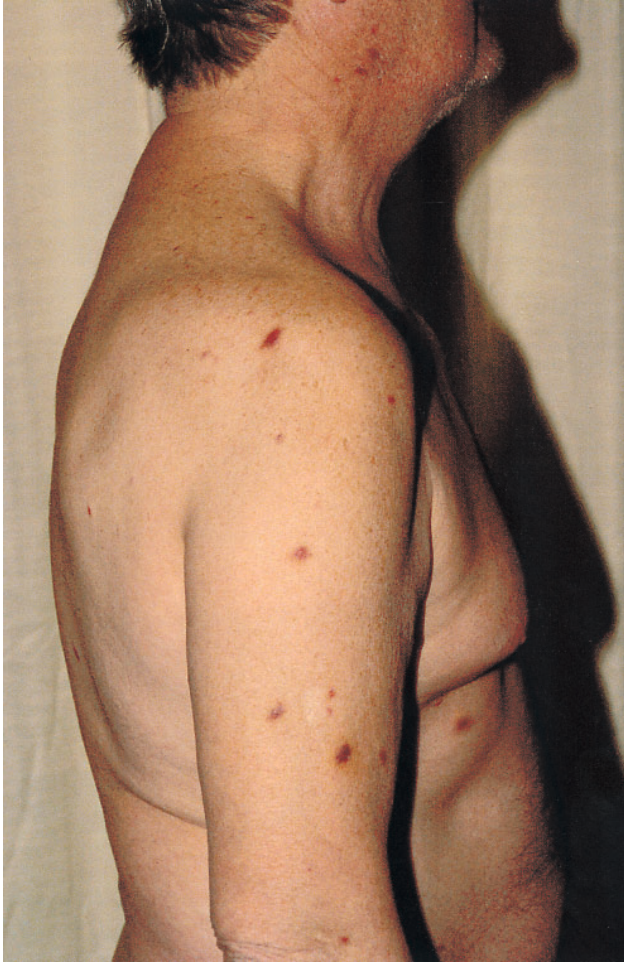

Figure 1. Cutaneous lesions in a patient with Wegener's granulomatosis and Kaposi's sarcoma.

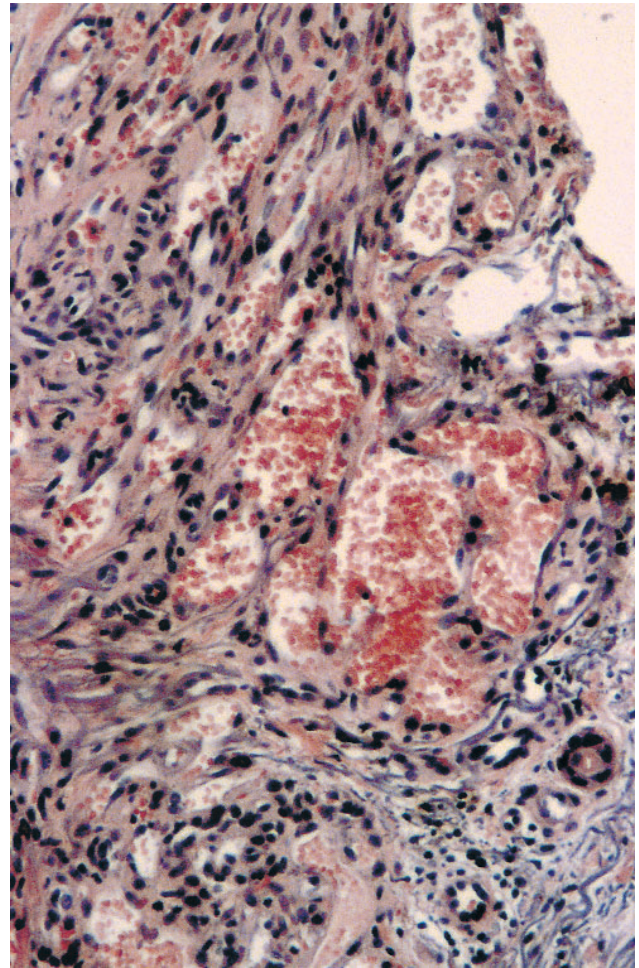


Figure 2. Left arm skin biopsy. Spindle shaped cells typical of Kaposi's sarcoma (H&E, original magnification $\times 200$).

and who experience abnormal cellular immunity, either iatrogenic or associated with HIV infection. In acquired immune deficiency syndrome, KS is linked to CD4 cell depletion, and antiretroviral therapy can improve the course of the disease. Iatrogenic KS occurs in patients receiving immunosuppressive therapy. Organ transplant recipients have a 0.5% overall risk of KS, and the incidence correlates with the degree of immunosuppression^{2,4}.

Therapy with corticosteroids is a known risk factor for KS in nontransplant patients⁵. The average time between the beginning of the therapy and the appearance of KS varies from 13.7 to 27.5 months, but patients from ethnic backgrounds known to be more susceptible to classic KS (Eastern European, Mediterranean, and Jewish origins) may develop the iatrogenic variety of KS earlier⁵. Although the patient described here had none of these ethnic backgrounds, he developed iatrogenic KS 2 months after the beginning of immunosuppressive therapy. The reason for this early presentation is difficult to explain. The seropositivity for HHV-8 when immunosuppressive therapy was started could play a

role in the duration of this latent period, since seronegative patients may develop KS later depending on how rapidly they become infected with HHV-8. It is possible to speculate that the bisexual practices of our patient, a known and strong risk factor for HHV-8 infection, could have made him more at risk to be seropositive for HHV-8 at the time of immunosuppression, thus contributing to the early presentation of KS.

Another important point was the markedly low lymphocyte cell count of the patient that we attribute to the combined effects of prednisone and cyclophosphamide. Fauci described the effects of corticosteroids on circulating lymphocytes in 1975⁶. Lymphocytopenia is transient and maximal 4 to 6 hours after administration of corticosteroids, returning to normal values in 24 to 48 hours^{6,7}. T lymphocytes are more reduced than B lymphocytes and CD4 cells are more depleted, resulting in a decrease in the CD4/CD8 ratio^{8,9}. Redistribution of lymphocytes in the bone marrow and possibly direct suppression of lymphocyte proliferation can explain this transient lymphocytopenia⁶. Cyclophosphamide has a greater effect on B cell depletion. Low doses increase the

CD4/CD8 ratio, but higher doses (600–700 mg/m² intravenously) may decrease it⁸.

Treatment of corticosteroid induced KS consists in reducing the dose as much as possible and considering excision, local radiotherapy, or systemic chemotherapy if the underlying disease is not well controlled^{2,5}. Progression or recurrence of KS has been described after reinstatement of corticotherapy⁵. In our patient the lesions disappeared with decrease and cessation of prednisone despite continuation of low dose cyclophosphamide, again suggesting that the corticotherapy was the main factor associated with this complication.

Corticosteroids are widely used in rheumatology and can be associated with the iatrogenic form of KS. To our knowledge, this is the second case report of KS in association with Wegener's granulomatosis¹⁰.

REFERENCES

1. Fitzpatrick TB, Johnson RA, Wolff K, Polano MK, Suurmond D. Kaposi's sarcoma. In: Fitzpatrick TB, Johnson RA, Wolff K, Suurmond D, editors. Color atlas and synopsis of clinical dermatology. 3rd ed. New York: McGraw-Hill; 1997:926-33.
2. Antman K, Chang Y. Medical progress: Kaposi's sarcoma. *N Engl J Med* 2000;342:1027-38.
3. Chang Y, Cesarman E, Pessin MS, et al. Identification of herpesvirus-like DNA sequences in AIDS-associated Kaposi's sarcoma. *Science* 1994;266:1865-9.
4. Greenblatt RM. Kaposi's sarcoma and human herpesvirus-8. *Infect Dis Clin North Am* 1998;12:63-82.
5. Trattner A, Hodak E, David M, Sandbank M. The appearance of Kaposi's sarcoma during corticosteroid therapy. *Cancer* 1993;72:1779-83.
6. Fauci AS. Corticosteroids and circulating lymphocytes. *Transplant Proc* 1975;7:37-40.
7. Fauci AS, Dale DC. Alternate-day prednisone therapy and human lymphocyte subpopulations. *J Clin Invest* 1975;55:22-32.
8. Bast RC, Reinherz EL, Maver C, Lavin P, Schlossman SF. Contrasting effects of cyclophosphamide and prednisolone on the phenotype of human peripheral blood leucocytes. *Clin Immunol Immunopathol* 1983;28:101-14.
9. Ginsburg C, Guillevin L, Sauvaget F, Lhote F, Jarrousse B, Komarover H. Systemic diseases treated by corticoids, plasma exchange and cyclophosphamide: infectious complications and lymphopenia [French]. *Ann Med Interne Paris* 1993;144:15-9.
10. Erban SB, Sokas RK. Kaposi's sarcoma in an elderly man with Wegener's granulomatosis treated with cyclophosphamide and corticosteroids. *Arch Intern Med* 1998;148:1201-3.