

# Gynecomastia and Sexual Impotence Associated with Methotrexate Treatment

MARIA ANGELES AGUIRRE, ANTONIO VÉLEZ, MANUEL ROMERO, and EDUARDO COLLANTES

**ABSTRACT.** Methotrexate (MTX) is the disease modifying antirheumatic drug most frequently used for rheumatoid and psoriatic arthritis (PsA). Several reports associate sexual dysfunction to MTX use. We describe 2 cases of sexual impotence and gynecomastia in patients with PsA treated with MTX. Although the mechanism underlying MTX induced sexual dysfunction is unknown, the potential consequences should be taken in account in view of the steady increase in the number of patients treated with this drug. (J Rheumatol 2002;29:1793–4)

*Key Indexing Terms:*  
METHOTREXATE

GYNECOMASTIA

IMPOTENCE

Since the 1980s, methotrexate (MTX) has been the disease modifying antirheumatic drug most frequently used to treat rheumatoid arthritis (RA) and the polyarticular form of psoriatic arthritis (PsA). This drug acts on folate metabolism by inhibiting dihydrofolate reductase (DHFR) and other folate dependent enzymes such as thymidylate synthetase and 5-aminoimidazole-4-carboxamide-ribonucleotide transformylase (AICAR)<sup>1-3</sup>. In this way, MTX depletes folate, which is required for purine and pyrimidine synthesis. Additional effects of MTX include decreasing the production of IgM rheumatoid factor and interleukin 1 (IL-1) and IL-2, and reducing polymorphonuclear chemotaxis and IL-6 activity<sup>2,4</sup>. MTX thus possesses immunosuppressant and antiinflammatory properties.

Although MTX is generally well tolerated, it has some side effects, mainly on the central nervous system, liver, blood, and lungs<sup>5,6</sup>. Several cases of sexual dysfunction (diminished libido, sexual impotence)<sup>7-11</sup> and gynecomastia<sup>12-14</sup> in men with RA receiving MTX treatment have been reported.

We discuss 2 men with PsA presenting with sexual impotence and gynecomastia following treatment with MTX.

## CASE REPORTS

*Case 1.* A 42-year-old man with no other pathological history of interest was diagnosed with PsA in its axial and peripheral forms in 1983; treatment with the nonsteroidal antiinflammatory drug (NSAID) ketoprofen had pro-

vided acceptable clinical control of the disease. In February 1997, he had an outbreak of polyarticular inflammation in both carpi, the distal interphalangeal joints, and the knees. MTX therapy of a weekly oral dose of 7.5 mg plus a folate supplement and indomethacin (100 mg/day) led to gradual improvement of the joint and skin symptoms. One year after treatment was started, he experienced erectile dysfunction and painful expansion of both breasts. Examination revealed painful asymmetric bilateral gynecomastia (Figure 1), with normal testicles. A biochemical analysis including the typical investigations for renal and hepatic function in addition to thyroxine, thyrotropic hormone, prolactin, follicle stimulating hormone (FSH), luteinizing hormone (LH), estradiol, testosterone, and chorionic gonadotropin ( $\beta$ -HCG) provided values within the normal ranges (Table 1). Several weeks after reduction of the MTX treatment, gynecomastia subsided and erectile function was recovered.

*Case 2.* A 30-year-old man diagnosed with polyarticular PsA in 1994 had been taking NSAID (indomethacin 100 mg/day) and auranofin (6 mg/day), which provided effective clinical control of the disease. In late 1998, he had an inflammatory outbreak and the auranofin treatment was suspended as inefficient. In February 1999, treatment with a 7.5 mg weekly oral dose of MTX was started in addition to a folate supplement, indomethacin (150 mg/day), and deflazacort (9 mg/day), which improved the clinical picture.

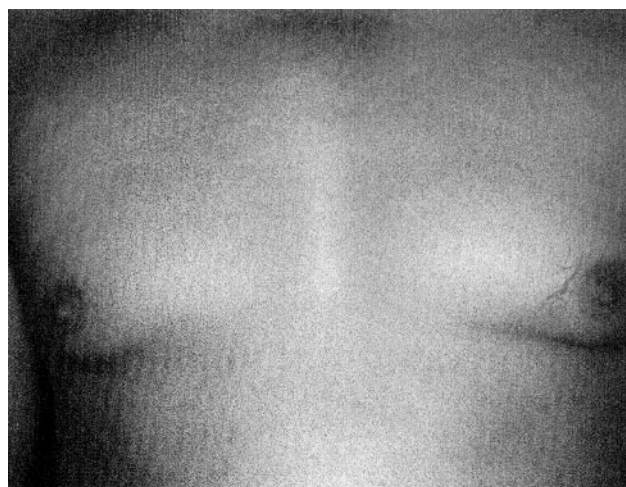


Figure 1. Bilateral gynecomastia in a patient with PsA under MTX treatment (Case 1).

From the Servicio Reumatología and Sección Dermatología, Hospital Universitario Reina Sofía, Universidad de Córdoba, Córdoba, Spain.

M.A. Aguirre, MD, Rheumatologist; A. Vélez, MD, Dermatologist; M. Romero, MD, Rheumatologist; E. Collantes, MD, Professor of Rheumatology and Chief, Service of Rheumatology.

Address reprints requests to Dr. M.A. Aguirre, Servicio de Reumatología, Hospital Universitario Reina Sofía, Avda Menéndez Pidal s/n, 14014 Córdoba, Spain. E-mail: angelesaguirre@supercable.es

Submitted December 19, 2001; revision accepted February 18, 2002.

Table 1. Hormone levels in 2 patients with PsA under MTX treatment.

Hormone	Normal Values	Case 1	Case 2
Thyroxine	0.7–1.48 ng/dl	1.2	1.1
TSH	0.35–4.94 mU/l	3.02	1.78
FSH	1.3–13.5 U/l	2.8	3.3
LH	1.8–8.16 U/l	4.7	2.2
Prolactin	2.58–18.12 µg/l	13.3	13.2
Estradiol	25–107 ng/l	35	18
Testosterone	1.7–8.4 µg/l	3.5	3.9
β-HCG	0–5 mU/ml	1	1

Two years after treatment was started, he was seen for erectile impotence and expansion of both breasts. Examination revealed asymmetric bilateral gynecomastia, but was otherwise normal. Biochemical investigation for renal, hepatic, and hormonal functions provided normal values for all. The MTX treatment was suspended, and a few weeks later gynecomastia subsided and sexual function was recovered.

## DISCUSSION

We studied 2 cases of patients with PsA taking MTX who presented with erectile impotence and gynecomastia. These symptoms were thought to be secondary to MTX administration, as they subsided after reduction of the drug while maintaining the rest of the treatment.

Sexual dysfunction associated with treatment with low dose MTX is a rare occurrence. Only 13 cases of sexual impotence<sup>7-11</sup> and 5 of gynecomastia<sup>12-14</sup> related to MTX administration have been reported in recent years. The symptoms appeared 2 weeks to 4 years after the therapy was started and the weekly doses ranged from 5 to 20 mg. Symptoms subsided within a few weeks after withdrawal or reduction of MTX.

In our patients, the symptoms appeared at a relatively late stage — one and 2 years after start of treatment with MTX; however, they reverted after reduction of the drug. No alterations of renal, hepatic, or hormonal functions were observed in the biochemical analyses. In only one case among those previously reported involving sexual impotence were hormone levels reported (specifically testosterone, prolactin, and estradiol, which were all normal)<sup>11</sup>. Also, only 2 cases of MTX related gynecomastia exhibited abnormal hormone levels, namely, low testosterone levels with normal gonadotropin concentrations in one patient<sup>12</sup> and elevated FSH and LH levels, suggesting testicular failure, in the other<sup>14</sup>.

The mechanism through which MTX causes these changes is unknown. Because MTX is metabolized by the liver, it has been hypothesized that the drug might act at that level. Thus, MTX might disrupt the estrogen–testosterone balance (i.e., increase estrogen activity relative to testos-

terone activity), which is the origin of most cases of gynecomastia<sup>15</sup>. This might result from increased aromatization of androgenic agents, enhanced synthesis of androgen carriers (bioavailability of which would thus be reduced), or increased estrogen bioavailability resulting from removal from their carrier proteins. One other possible mechanism of action for MTX is interaction with intracellular testosterone receptors.

While infrequent, sexual dysfunction associated with treatment with low doses of MTX should be considered in rheumatic patients on account of its reversibility. The actual prevalence of this problem is unknown; more detailed investigation may reveal a higher incidence of the associated symptoms.

## REFERENCES

- Bacon PA, Salmon M. Modes of action of second line agents. *Scand J Rheumatol* 1987;64 Suppl:17-24.
- Segal R, Yaron M, Tartakovsky B. Methotrexate: mechanism of action in rheumatoid arthritis. *Semin Arthritis Rheum* 1990;20:190-9.
- Kremer JM. The mechanism of action of methotrexate in rheumatoid arthritis: the search continues. *J Rheumatol* 1994;21:1-5.
- Cronstein BN, Merrill JT. Mechanisms of the effects of methotrexate. *Bull Rheum Dis* 1996;45:6-8.
- Espinoza LR, Zakraoui L, Espinoza CG, et al. Psoriatic arthritis: clinical response and side effects to methotrexate therapy. *J Rheumatol* 1992;19:872-7.
- Furst DE. The rational use of methotrexate in rheumatoid arthritis and other rheumatic diseases. *Br J Rheumatol* 1997;36:1196-204.
- Blackburn WD, Alarcón GS. Impotence in three rheumatoid arthritis patients treated with methotrexate [letter]. *Arthritis Rheum* 1989;32:1341-2.
- M'Bappe P, De Bandt M, Meyer O, Kahn MF, Palazzo E. Five cases of impotence during methotrexate therapy for rheumatologic diseases [abstract]. *Arthritis Rheum* 1992;35 Suppl:149.
- Riba N, Moreno F, Costa J, Olivé A. Aparición de impotencia en relación al uso de metotrexate [letter]. *Med Clin (Barc)* 1996;106:558.
- Ibanez Ruan J, Gómez Rodríguez N, Ferreiro Seoane LF. Disfunción sexual asociada al tratamiento con metotrexato. *Rev Esp Reumatol* 1998;25:313-5.
- Thomas E, Koumouvi K, Blotman F. Impotence in a patient with rheumatoid arthritis treated with methotrexate [letter]. *J Rheumatol* 2000;27:1821-2.
- Del Paine DW, Leek JC, Jakle C, Robbins DL. Gynecomastia -associated with low dose methotrexate therapy [letter]. *Arthritis Rheum* 1983;26:691-2.
- Thomas E, Leroux JL, Blotman F. Gynecomastia in patients with rheumatoid arthritis treated with methotrexate [letter]. *J Rheumatol* 1994;21:1777-8.
- Finger DR, Klippe GL. Gynecomastia following low dose methotrexate therapy for rheumatoid arthritis [letter]. *J Rheumatol* 1995;22:796-7.
- Braunstein GD. Gynecomastia. *N Engl J Med* 1993;328:490-5.