Editorial

The Hand: A Second Face?



Die Hand ist sowie das zweite Gesicht der Frau [The hand is like a woman's second face.]

— German saying

The patient with rheumatoid arthritis (RA) who has severe, advanced involvement in the upper and lower limb joints may require a hierarchy of reconstruction procedures, selected according to the patient's greatest needs. Maintenance of ambulation (lower limb) and maintenance of independence in self-care (upper limb) take priority in the surgical management of these patients[1]. The suggestion that improvement of the appearance of the hand is an important goal in this context is likely to be dismissed. Add into the decision making process a consideration of escalating health care costs in Canada, with limited surgical resources and long waiting lists, and esthetic considerations in the rheumatoid hand may seem even less significant.

In the RA hand, the primary goals for metacarpophalangeal (MCP) arthroplasty include improvement of hand function, relief of pain, and correction of deformity. For the most part, surgeons that address correction of deformity do so in the context of functional improvement, rather than improvement of appearance. Nevertheless, there is reason to believe that the appearance of the deformed rheumatoid hand is an important issue to many patients, that correction of deformity to improve appearance is a valued benefit of hand surgery, and that therefore it is incumbent upon caregivers to give systematic consideration to this issue.

Surgery is currently considered to be indicated in the RA hand with significant flexion contractures in order to open the hand for grip, in a joint stiff in extension to permit flexion, in progressive and persistent ulnar drift to place the fingers in a position of function, and in destroyed joints to relieve pain and provide stability or mobility[2-8]. Indications for surgery are strengthened where both hands are involved and in cases where improved hand function will permit use of a cane for ambulation[8].

The pain pattern is different in the RA patient, who experiences pain and stiffness during intermittent active periods of the disease. Late in the disease, despite extensive joint destruction, pain is often not severe in RA and is typically not the primary indication for surgery.

After MCP reconstruction, ulnar drift deformity is substantially reduced, and the index finger is placed in a position that improves pinch function. However, objectively measured improvement in grip function is not highly consistent or predictable, and improvement in the mean active range of MCP motion is modest or minimal, although the shift in the arc of motion usually permits greater functionality[3,5-11]. Improvement in function is also dependent on the condition of the proximal interphalangeal joints and the thumb[12].

Despite modest or no improvement in objectively measured functional outcomes, 68% to 100% of patients subjectively indicated a substantial improvement in function following surgery, which may be partially attributed to improved performance of activities of daily living, elimination of pain, and improved stability through the joint[2,4,5,8-10,13-16]. Further, several studies report that the majority of RA patients (86%–100%) indicated satisfaction with improved appearance of the hand almost immediately following surgery[8,13-16]. Finally, 84% to 100% of patients report overall satisfaction with MCP reconstruction[3,6,7,9,14]. A retrospective study of 26 patients by Mandl, *et al* in this issue[17] reports that 69% of patients expressed overall satisfaction with MCP reconstruction, and postoperative hand appearance and pain were the outcome measures most highly correlated with overall patient satisfaction.

Why does a patient express high satisfaction with an operation where improvement in grip function is not highly consistent or predictable and range of motion may remain limited? To what degree might the esthetic appearance of the hand be an element of patient satisfaction with this procedure? Some studies acknowledge that patients appreciated the esthetic improvement of their hands following surgery[5,8,9,14]. Mandl, *et al*[17] reported a Spearman correlation of 0.6 to 0.7 between postoperative hand appearance and

See Metacarpophalangeal arthroplasty in rheumatoid arthritis: What determines satisfaction with surgery? *page 2488*

Personal non-commercial use only. The Journal of Rheumatology Copyright © 2002. All rights reserved.

Downloaded on April 18, 2024 from www.jrheum.org

overall patient satisfaction with surgery. Swanson, *et al*[18] emphasized assessment of both the passive and active elements in relation to general appearance, rotational deformity, scarring, coordination, stiffness, and residual joint imbalance, where both the examiner and patient rate the cosmetic improvement after surgery on a 3 point scale of minimum (1), moderate (2), and marked (3). However, no systematic or standardized attempt has been made to specifically measure patient satisfaction with surgical change in the appearance of the hand or to compare it with satisfaction with other aspects of the results of the surgery.

If visible improvement of the deformity and appearance of the RA hand following surgery is to be systematically considered, it could be reviewed under 3 criteria: (1) patient motivation and indications for surgery; (2) patient rating of the quality of the outcome; and (3) patient satisfaction with the outcome.

In a pilot study to determine the relative role of esthetics versus function and pain in patients' motivations for surgery and in patients' perception of and satisfaction with the outcome, we conducted a retrospective review of 22 patients with RA (95% female; mean age 66 yrs; mean disease duration 18.5 yrs, mean followup period 5 yrs), who had undergone MCP reconstruction for digits 2–5 inclusive, performed by one of the authors (ERB). Patient views were collected through interview, using the esthetics subscale of the Michigan Hand Outcomes Questionnaire[19,20], and a purpose written questionnaire using 7-point Likert scale questions specifically developed to assess patients' reasons to undergo MCP reconstruction (motivation), rating of outcome, and satisfaction with outcome, separately for hand appearance, function, and pain (Appendix I). Means were determined for each question, and a chi-square test was used to compare means and determine a statistically significant difference at $p = 0.05$. Median differences in patient agreement were also compared by Mann-Whitney test.

A desire for improvement in hand appearance was found to be as strong a patient motivator in the decision to have hand surgery as relief of pain, but less strong than a desire for improvement in hand function ($p < 0.05$) (Figure 1, Motivation). When patients were asked to rate the outcomes of the surgery, there was no median significant difference between improved appearance and improved function outcome ratings, and improved appearance outcome was rated superior to pain relief outcome after surgery ($p < 0.05$) (Figure 1, Outcome).

When asked to rate their satisfaction with the surgery, patients expressed higher satisfaction with improved appearance and improved function outcomes than with pain relief outcome. Patients were at least as satisfied with improved appearance outcome as with improved function outcome, with a trend towards higher satisfaction with appearance than function (Figure 1, Satisfaction). In a subset of 6 patients, the reconstructed hand was less functional than the non-operated hand, as defined by Jamar grip strength, Jamar pinch strength, active range of motion, and the Jebsen hand function test. All 6 patients reported high satisfaction with their reconstructed hands and expressed the desire to have their second hand reconstructed to correct deformity, even though measured function was superior in the non-operated hand.

This simple examination of surgical patients' motiva-

Appendix I. Patient survey questionnaire.

MP RECONSTRUCTION: INDICATIONS
A SURVEY OF PATIENT OPINIONS

We are interested in your reasons for having hand surgery.
Please provide your opinion by responding to each statement below.

1) I had surgery to improve the function of my hand (ability to use my hand).

completely agree 1 2 3 4 5 6 7 completely disagree

2) I had surgery to improve the appearance (look) of my hand.

completely agree 1 2 3 4 5 6 7 completely disagree

3) I had surgery to decrease the pain I had in my hand.

completely agree 1 2 3 4 5 6 7 completely disagree

4) Please rank in order of importance the reasons you decided to have hand surgery.

1= most important reason
2= second most important reason
3= third most important reason

_____ to improve the appearance (look) of my hand
_____ to improve my hand function (ability to use my hand)
_____ to decrease my hand pain
_____ other _____

Personal non-commercial use only. The Journal of Rheumatology Copyright © 2002. All rights reserved.

Downloaded on April 18, 2024 from www.jrheum.org

Appendix I. Continued

We are also interested in any comments you would like to make about why you choose to have hand surgery.

Comments:

Thank you very much for your input.

Now, we are interested in how (or if) you feel the surgery affected your hand. Please provide your opinion by responding to each statement below.

5) After surgery, my hand was more useful.

completely agree 1 2 3 4 5 6 7 completely disagree

6) After surgery, the appearance of my hand was improved.

completely agree 1 2 3 4 5 6 7 completely disagree

7) After surgery, I had less pain in my hand.

completely agree 1 2 3 4 5 6 7 completely disagree

8) What was affected most by the surgery? Please rank what improved the most following surgery.

1=most improved
2=somewhat improved
3=least improved
N= not improved

_____ the appearance (look) of my hand
_____ my ability to do things with my hand *or* the usefulness of my hand
_____ the decrease in hand pain

Finally, we would like to know about how satisfied you were with the result of your hand surgery.

9) I am satisfied with the appearance (look) of my hand after surgery.

completely agree 1 2 3 4 5 6 7 completely disagree

10) I am satisfied with my hand function (ability to use my hand) after surgery.

completely agree 1 2 3 4 5 6 7 completely disagree

11) I am satisfied with the decrease in hand pain I experienced after surgery.

completely agree 1 2 3 4 5 6 7 completely disagree

12) Overall, I am satisfied with my hand after surgery.

completely agree 1 2 3 4 5 6 7 completely disagree

13) Given the option, I would have the surgery done again.

completely agree 1 2 3 4 5 6 7 completely disagree

We also interested in any comments you would like to make about the affect surgery had on your hand, and how you satisfied you are or aren't with the results of the surgery.

Comments:

Thank you very much for your input.

tions and satisfaction with outcomes of surgery, while not conclusive, suggests that these patients were strongly motivated to have their hand deformity or appearance corrected, that they considered their hand appearance improved by surgery, and that their satisfaction with surgery was partly predicated on the improvement with the esthetics of their hand.

A patient with RA who has a MCP flexion deformity that prevents opening of the hand, complicating the simple act of shaking hands, faces a physical, psychological, and social barrier when greeting another person. Rheumatologists may recognize the look of anxiety that passes across a patient's face when the physician offers to shake hands and, subsequently, the look of relief when the hand is grasped in a manner that conveys understanding of the deformity and minimizes discomfort and embarrassment (Figure 2).

Personal non-commercial use only. The Journal of Rheumatology Copyright © 2002. All rights reserved.

Downloaded on April 18, 2024 from www.jrheum.org

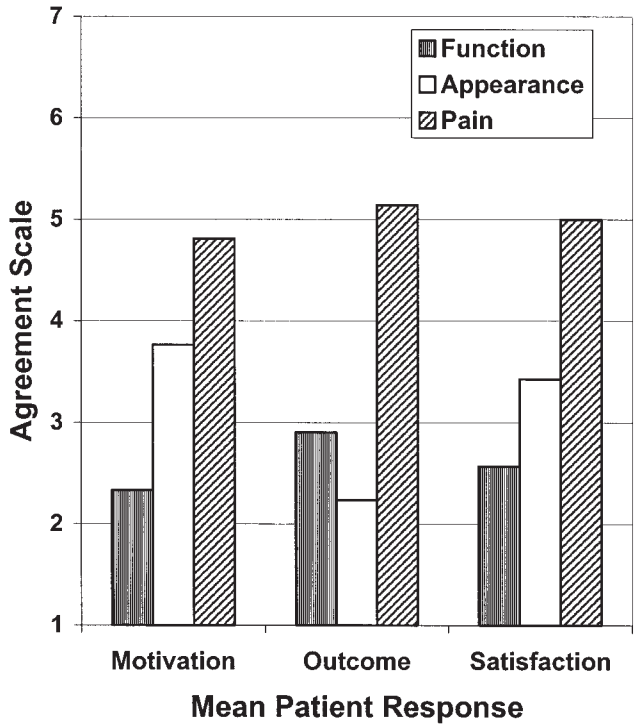

Figure 1: Median patient response (n = 22) on a 7-point Likert agreement scale, where 1 represents strong agreement and 7 represents strong disagreement, with statements that function, hand appearance, and pain were: a strong motivator for hand surgery (Motivation); improved following surgery (Outcome); and were satisfactory after surgery (Satisfaction).

Correction of disfigurement and improvement of appearance are widely accepted primary indications for surgery in other fields, particularly with respect to reconstructive or esthetic surgery of the face and the breast. As defined by the American Society of Plastic Surgeons[21], reconstructive surgery is performed "on abnormal structures to improve function," but also, and one could argue, more frequently, "to approximate a more normal appearance." Common reconstructive surgical procedures with a substantial cosmetic component include breast reduction, correction of breast asymmetry, burn scar revision, and improvement of congenital deformities and keloid formations of the face. These are mainstream surgical activities supported by publicly funded billing criteria and listed in the International Classification of Disorders (ICD), reflecting their legitimacy. Esthetic surgery is performed to "reshape normal structures of the body to improve the patient appearance and self-esteem"[21].

Attempts to examine patient motivations, define surgical goals, assess outcome measures, and ascertain patient satisfaction for reconstructive and esthetic surgical procedures of the face and breast have been limited[22]. Appearance outcome measures are often highly subjective, consisting of panels of surgeons, medical staff, and patients that rank pre and postoperative photographs on a simple ordinal scale, where each grade is generally poorly defined, if at all, or using a visual analog scale[22-26]. Other outcome measure studies have applied quality of life measures such as the Medical Outcome Study Short Form-36[27-29], and psychological questionnaires to evaluate patient anxiety, self-esteem and depression, such as the Crown-Crisp Experiential Index[23,30,31]. Recently, several new objective grading

Figure 2. The hand — a second face?

Personal non-commercial use only. The Journal of Rheumatology Copyright © 2002. All rights reserved.

Downloaded on April 18, 2024 from www.jrheum.org

Appendix II. Surgeon survey questionnaire.

MP RECONSTRUCTION: INDICATIONS AND OUTCOMES
A SURVEY OF EXPERT OPINIONS

Please provide your opinion by responding to each statement below.

completely agree 1 2 3 4 5 6 7 completely disagree

*First, we would like to know about your opinions regarding **indications** for MP reconstruction.*

1. Functional improvement is a primary/significant indication for MP reconstructive surgery.

completely agree 1 2 3 4 5 6 7 completely disagree

2. Hand deformity /appearance is a primary/significant indication for MP reconstructive surgery.

completely agree 1 2 3 4 5 6 7 completely disagree

*Now, we would like to know about your opinions regarding **outcome** following MP reconstruction.*

3. Following MP reconstruction, MP flexion is consistently more restricted/limited in D4 and D5 than in D2 and D3.

completely agree 1 2 3 4 5 6 7 completely disagree

4. Following MP reconstruction, increased MP extension is accompanied by a significant decrease in flexion.

completely agree 1 2 3 4 5 6 7 completely disagree

5. Following MP reconstruction, the arc of MP motion doesn't significantly increase but is shifted toward a more extended position.

completely agree 1 2 3 4 5 6 7 completely disagree

*Finally, we would like to know about your opinion regarding MP **implant design.***

6. There is a need for a new implant design in MP reconstructive surgery.

completely agree 1 2 3 4 5 6 7 completely disagree

7. An MP implant design that encourages MP *flexion* would be helpful.

completely agree 1 2 3 4 5 6 7 completely disagree

8. An MP implant design that encourages MP *extension* would be helpful.

completely agree 1 2 3 4 5 6 7 completely disagree

systems have been developed for esthetic outcome evaluation of cosmetic breast and facial surgery[32-35]. These provide a standardized evaluation of the efficacy of these treatments in achieving specific goals. However, we have found no report that systematically assessed the esthetic outcome of the rheumatoid hand following surgical procedures.

We conducted an informal survey of 25 hand surgeons active in rheumatoid hand reconstruction in 4 countries by mail questionnaire, utilizing Likert scales, to elucidate the reasons for performing surgery (Appendix II). Thirty-five per cent of the 23 respondents agreed that hand deformity is a primary indication, 25% neither agreed nor disagreed, and 40% disagreed (responding that hand deformity was not in their view a primary reason for MCP reconstruction). While some surgeons acknowledge that esthetic improvement of the hand may be a consideration that influences the patient's satisfaction with the surgery, they tend to emphasize that it should only be a secondary indication for surgery[9].

Outcome analysis of rheumatoid hand surgery usually includes clinician-focused objective tests that evaluate functional outcome (grip strength, pinch strength, active range of motion). However, a search of the literature has found only one study utilizing the patient-focused Arthritis Impact Measurement Scale for evaluation of MCP arthroplasty[36]. Since our preliminary data indicate that appearance may be a motivating factor for a patient to have surgery, and since patient satisfaction is high despite moderate functional outcomes, it would be valuable to introduce more patient-focused assessments. These might include patient specific indices that allow patients to choose the outcome measures that are important prior to their surgery, which may include esthetic appearance.

This issue could be better clarified with a prospective study that follows patients from their first visit with the surgeon to one or more years postoperatively. The study would utilize patient specific indices to define their motiva-

Personal non-commercial use only. The Journal of Rheumatology Copyright © 2002. All rights reserved.

Downloaded on April 18, 2024 from www.jrheum.org

tion for the surgery and their feelings regarding the deformity, in order to establish what is important, not only to the doctor, but also to the patient.

Our working hypothesis is the following: there is unmeasured motivation for patients who choose to have corrective surgery for a deformity of the rheumatoid hand and an unmeasured source of satisfaction after the surgery. This hypothesis is currently being tested in a prospective study. We seek to determine if esthetic considerations are important to the patients. The ultimate goal of this and other studies is to help us refine indications for surgery and to determine which operations are best received by patients. Ultimately, we want surgery to be evidence based, utilizing, among other factors, the determinants of patient motivation and satisfaction. There is no intention to recommend that esthetic appearance replace functional outcome as the primary indication for surgery. We do, however, believe that rheumatologists and orthopedic surgeons need to evaluate to what degree improvement of appearance is a legitimate and perhaps equally important indication for surgery of the hand in the RA patient, and to what degree esthetic improvement after surgery is valued by the patient.

ACKNOWLEDGMENT

The authors thank Nancy De Boni for creating the illustration, and Dagmar Gross for assistance with preparation of this manuscript.

EARL R. BOGOCH, MD, Msc, FRCSC,
Department of Surgery, University of Toronto,
Martin Family Centre for Arthritis Care
Mobility Program, St. Michael's Hospital,
55 Queen St. East, Suite 800,
Toronto, Ontario, M5C 1R6, Canada;
E-mail: bogoch@sympatico.ca and
MARIA G.P. JUDD, BSc, PT,
St. Michael's Hospital, Toronto.

Ms. Judd was supported by an unrestricted research grant from DePuy Canada, Inc.
Address reprint requests to Dr. Bogoch.

REFERENCES

1. Gschwend N. Multiple joint replacement in chronic rheumatoid arthritis: results, indications. Ther Umsch 1995;52:464-9.
2. Vliet Vlieland TPM, van der Wijk TP, Jolie IMM, Zwinderman AH, Hazes JMW. Determinants of hand function in patients with rheumatoid arthritis. J Rheumatol 1996;23:835-40.
3. Beevers DJ, Seedhom BB. Metacarpophalangeal joint prostheses: A review of the clinical results of past and current designs. J Hand Surg Br 1995;20:125-36.
4. Vermeiren JAM, Dapper MML, Schoonhoven LA, Merx PWJ. Isoelastic arthroplasty of the metacarpophalangeal joints in rheumatoid arthritis: A preliminary report. J Hand Surg Am 1994;19:319-24.
5. El-Gammal TA, Blair WF. Motion after metacarpophalangeal joint reconstruction in rheumatoid disease. J Hand Surg Am 1993;18:504-11.
6. Kirschenbaum D, Schneider LH, Adams DC, Cody RP. Arthroplasty of the metacarpophalangeal joints with use of silicone-rubber implants in patients who have rheumatoid arthritis. J Bone Joint Surg Am 1993;75:3-12.
7. Wood VE, Ichtertz DR, Yahiku H. Soft tissue metacarpophalangeal reconstruction for treatment of rheumatoid hand deformity. J Hand Surg Am 1989;14:163-74.
8. Mannerfelt L, Andersson K. Silastic arthroplasty of the metacarpophalangeal joints in rheumatoid arthritis. J Bone Joint Surg Am 1975;57:484-9.
9. Schmidt K, Witt K, Ossowski A, Miehlke RK. Therapy of rheumatoid destruction of the middle finger metacarpophalangeal joint with a Swanson silastic implant stabilized resection arthroplasty: comparative study of long and intermediate term results with and without implantation of titanium grommets [German]. Z Rheumatol 1997;56:287-97.
10. Lundborg G, Branemark, PI, Carlsson I. Metacarpophalangeal joint arthropasty based on the osseointegration concept. J Hand Surg Br 1993;13:693-703.
11. Nalebuff EA. The rheumatoid hand: Reflections on metacarpophalangeal arthroplasty. Clin Orthop Rel Res 1984;182:150-9.
12. Gschwend N, Raemy H, Nittner H, Ivosevic-Radovanovic D. Long-term results of endoprosthetic joint replacement and synovectomy. Handchir Mikrochir Plast Chir 1986;18:135-49.
13. Gellman H, Stetson W, Brumfield RH Jr, Costigan W, Kuschner H. Silastic metacarpophalangeal joint arthroplasty in patients with rheumatoid arthritis. Clin Orthop Rel Res 1997;342:16-21.
14. Vahvanen V, Viljakha T. Silicone rubber implant arthroplasty of the metacarpophalangeal joint in rheumatoid arthritis: a follow-up study of 32 patients. J Hand Surg 1986;11:333-9.
15. Blair WF, Shurr DG, Buckwalter JA. Metacarpophalangeal joint implant arthroplasty with a silastic spacer. J Bone Joint Surg 1984 Am;66:365-70.
16. Fleming SG, Hay EL. Metacarpophalangeal joint arthroplasty eleven year follow-up study. J Hand Surg Br 1984;9:300-2
17. Mandl LA, Galvin DH, Bosch JP, et al. Metacarpophalangeal arthroplasty in rheumatoid arthritis: What determines satisfaction with surgery? J Rheumatol 2002;29:2488-91.
18. Swanson AB, Goran-Hagert C, Swanson G. Evaluation of impairment of hand function. In: Hunter JM, Schneider L, Mackin E, Callahan A, editors. Rehabilitation of the hand. 3rd ed. St. Louis:Mosby; 1990.
19. Chung KC, Pillsbury MS, Walters MR, Hayward RA. Reliability and validity testing of the Michigan Hand Outcomes Questionnaire. J Hand Surg Am 1998;23:575-87.
20. Chung KC, Hamill JB, Walters MR, Hayward RA. The Michigan Hand Outcomes Questionnaire (MHQ): assessment of responsiveness to clinical change. Ann Plast Surg 1999;42:619-22.
21. American Society of Plastic and Reconstructive Surgeons. Procedures in plastic surgery. Arlington Heights, IL: ASPRS; 1989.
22. Jones SA, Bain JR. Review of data describing outcomes that are used to assess changes in quality of life after reduction mammaplasty. Plast Reconstr Surg 2001;108:62-7.
23. Ferreira MC. Evaluation of results in aesthetic plastic surgery: preliminary observations on mammaplasty. Plast Reconstr Surg 2000;106:1630-5.
24. Losken A, Bostwick J. Discussion. Evaluation of results in aesthetic plastic surgery: preliminary observations on mammaplasty. Plast Reconstr Surg 2000;106:1636-8.
25. Lowery JC, Wilkins EG, Kuzon WM, Davis JA. Evaluations of aesthetic results in breast reconstruction: An analysis of reliability. Ann Plast Surg 1996;36:601-7.
26. Barden RC, Ford ME, Wilhelm W, Rogers-Salyer M, Salyer KE. The physical attractiveness of facially deformed patients before and after craniofacial surgery. Plast Reconstr Surg 1988;82:229-35.
27. Klassen A, Jenkinson C, Fitzpatrick R, Goodacre T. Patients' health

Personal non-commercial use only. The Journal of Rheumatology Copyright © 2002. All rights reserved.

Downloaded on April 18, 2024 from www.jrheum.org

related quality of life before and after aesthetic surgery. Br J Plast Surg 1996;49:433-8.
28. Klassen A, Fitzpatrick R, Jenkinson C, Goodacre T. Should breast reduction surgery be rationed? A comparison of the health status of patients before and after treatment: Postal questionnaire survey. BMJ 1996;313:454-7.
29. Cole RP, Shakespeare V, Shakespeare P, Hobby JAE. Measuring outcome in low-priority plastic surgery patients using quality of life indices. Br J Plast Surg 1994;47:117-21.
30. Hollyman JA, Lacey JH, Whitfield PJ, Wilson JSP. Surgery for the psyche: A longitudinal study of women undergoing reduction mammoplasty. Br J Plast Surg 1986;39:222-4.
31. Crown S, Crisp AH. Manual of the Crown-Crisp Experiential Index. London: Hodder and Stoughton; 1979.
32. Alsarraf R, Larrabee WF Jr, Anderson S, Murakami CS, Johnson CM Jr. Measuring cosmetic facial plastic surgery outcomes: a pilot study. Arch Facial Plastic Surg 2001;3:198-201.
33. Panchal J, Marsh JL, Park TS, Kaufman B, Pilgram T. Photographic assessment of head shape following sagittal synostosis surgery. Plast Reconstr Surg 1999;103:1585-91.
34. Strasser EJ. An objective grading system for the evaluation of cosmetic surgical results. Plast Reconstr Surg 1999;104:2282-5.
35. Tapia A, Etxeberria E, Blanch A, Laredo C. A review of 685 rhytidectomies: A new method of analysis based on digitally processed photographs with computer processed data. Plast Reconstr Surg 1999;104:1800-10.
36. Colville RJI, Nicholson KS, Belcher HJCR. Hand surgery and quality of life. J Hand Surg Br 1999;24:263-6.

Personal non-commercial use only. The Journal of Rheumatology Copyright © 2002. All rights reserved.

Downloaded on April 18, 2024 from www.jrheum.org