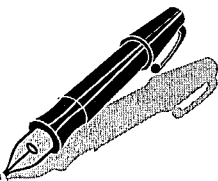


Correspondence



INSTRUCTIONS FOR LETTERS TO THE EDITOR

Editorial comment in the form of a Letter to the Editor is invited; however, it should not exceed 800 words, with a maximum of 10 references and no more than 2 figures (submitted as camera ready hard copy per Journal Guidelines) or tables and no subdivision for an Abstract, Methods, or Results. Letters should have no more than 3 authors. Full name(s) and address of the author(s) should accompany the letter as well as the telephone number, fax number, or E-mail address.

Contact: The Managing Editor, The Journal of Rheumatology, 920 Yonge Street, Suite 115, Toronto, Ontario M6J 3G7, CANADA. Tel: 416-967-5155; Fax: 416-967-7556; E-mail: jrheum@jrheum.com Financial associations or other possible conflicts of interest should always be disclosed.

Cyclosporin A in Treatment of Refractory Adult Polymyositis/Dermatomyositis

To the Editor:

Qushmaq, *et al*¹ in their concise review discuss the use of cyclosporin A (CSA) in patients with polymyositis and dermatomyositis.

We would like to stress the risk of myolysis as a side effect of CSA. Indeed, CSA itself or in combination with other drugs metabolized by cytochrome P450 3A4 may cause myopathy.

In our department we observed myolysis in a 66-year-old woman with psoriasis pustulosa et arthropatica. Taking both CSA (3 mg/kg/day) and cerivastatin (0.6 mg/day) together she developed myalgia of the extremities. Creatine kinase increased up to 1600 IU/l

Yamanishi, *et al* in 1993 described a 40-year-old patient with Behçet's disease. While taking CSA (6.35 mg/kg/day) this patient developed generalized myalgia and muscle weakness, accompanying marked elevation of creatinine kinase (4962 IU/l)². Similar cases have been described. In these cases the combination of CSA and HMG-CoA reductase inhibitors, a widely used class of drugs, caused myopathy³.

Thus the prescription of CSA treatment in patients with preexisting myopathy such as dermatomyositis or polymyositis should be considered carefully. Awareness about possible interactions of CSA with other drugs metabolized by the cytochrome P450 enzyme system appears mandatory.

JOERG WENZEL, MD; THOMAS BIEBER, MD, Polyclinic for Dermatology, Universitätsklinikum Bonn, 53105 Bonn, Germany.

REFERENCES

1. Qushmaq KA, Chalmers A, Esdaile JM. Cyclosporin A in the treatment of refractory adult polymyositis/dermatomyositis: population based experience in 6 patients and literature review. *J Rheumatol* 2000;27:2855-9.
2. Yamanishi Y, Ishibe Y, Taooka Y, Mukuzono H, Aoi K, Yamana S. A case of cyclosporin A-induced myopathy. *Ryumachi* 1993; 33:63-7.

3. Meier C, Stey C, Brack T, Maggiorini M, Risti B, Krahenbuhl S. Rhabdomyolysis in patients treated with simvastatin and cyclosporin: role of the hepatic cytochrome P450 enzyme system activity. *Schweiz Med Wochenschr* 1995;125:1342-6.

Dr. Chalmers replies

To the Editor:

We read with interest about the risk of myolysis as a side effect of cyclosporin A.

Given the cases that these authors cited, it is unlikely that CSA itself was the sole cause of myolysis or myopathy since, in all 3 cases, other drugs were being used that either on their own or perhaps potentiated by cyclosporine can induce myopathy. The statins as a group of drugs are well known to induce myopathy and myalgia, and colchicine in the dosages reported by Yamanishi, *et al*¹ both orally and intravenously has been associated with the development of profound myopathy, weakness, and elevations of creatine phosphokinase.

Fortunately, the international and Canadian guidelines for use of cyclosporine in rheumatoid arthritis used in our clinic help us determine guidelines for treatment of other connective tissue diseases, and indicate that HMG CoA reductase inhibitors (a class of lipid lowering agents) should not be used in conjunction with cyclosporine. We have not made it a practice to use these drugs with cyclosporine.

As for colchicine, it is known to cause myopathy. This is even referenced in the drug section of *MD Consult*. There remains the possibility in the described case that cyclosporine potentiated the effects of colchicine, and by the mechanism of cyclosporine increasing the creatinine, further increased the concentration of colchicine in the patient and thus caused very significant myalgia.

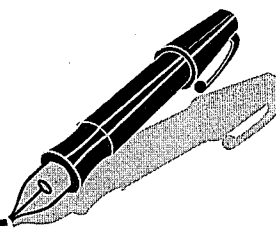
I am not aware of references supporting cyclosporin A induced myopathy as a function of cyclosporine alone.

ANDREW CHALMERS, MD, FRCPC, Mary Pack Arthritis Centre, Vancouver, British Columbia V5Z 1L7, Canada

REFERENCE

1. Yamanishi Y, Ishibe Y, Taooka Y, Mukuzono H, Aoi K, Yamana S. A case of cyclosporin A-induced myopathy. *Ryumachi* 1993; 33:63-7.

Letters



Occupational Factors in Systemic Sclerosis

To the Editor:

I read with interest the article by Lambert, *et al* reporting a case of hypothenar hammer syndrome followed by systemic sclerosis (SSc)¹.

This report illustrates that many workers exposed to silica are also exposed to repetitive hand trauma and to vibrating hand tools. It is therefore not unusual to observe a high prevalence of Raynaud's phenomenon or hypothenar hammer syndrome in this category of workers. In addition, digital sclerosis and necrosis can be seen in vibration white finger (VWF) even

in the absence of silica exposure². The distinction of SSc from VWF is therefore difficult, especially in workers also presenting silicosis. In consequences, the contribution of silica exposure to SSc may be overestimated among workers exposed to vibrating hand tools^{3,4}.

If vibration exposure may induce or contribute to the development of SSc is unknown, but it may be suspected. For example, the risk of developing SSc with silica exposure is statistically increased only in men and not in women, who are less exposed to vibrating hand tools⁵. In addition, similar skin and vascular histopathological findings as well as high plasma levels of endothelin-1 are observed in both SSc and VWF⁶. Endothelial injury with induction of autoimmunity has been proposed as a possible physiopathological mechanism in SSc⁷.

The relationship between SSc, silica, and vibration exposure has to be clarified. The fact that not all exposed persons develop both silicosis and SSc suggests silica alone does not cause SSc⁸. The case reported by Lambert, *et al* is a good example of the complexity of this problem. Further clinical and epidemiological studies are therefore warranted.

BERNARD NOËL, MD, Department of Dermatology, CHUV, CH-1011 Lausanne, Switzerland. E-mail: bernard.noel@chuv.hospvd.ch

REFERENCES

1. Lambert M, Hatron PY, Hachulla E, Devulder B. Hypothenar hammer syndrome followed by systemic sclerosis. *J Rheumatol* 2000;27:2516-7.
2. Noel B, Holtz J, Savolainen H, Depairon M. Hand-arm vibration syndrome with proximal ulnar artery occlusion. *Vasa* 1998; 27:176-8.
3. Walsh SJ. Effects of non-mining occupational silica exposure on proportional mortality from silicosis and systemic sclerosis. *J Rheumatol* 1999;26:2179-85.
4. Silman AJ, Jones S. What is the contribution of occupational environmental factors to the occurrence of scleroderma in men? *Ann Rheum Dis* 1992;51:1322-4.
5. Mayes MD. Epidemiologic studies of environmental agents and systemic autoimmune diseases. *Environ Health Perspect* 1999;107 Suppl 5:743-8.
6. Noel B. Pathophysiology and classification of the vibration white finger. *Int Arch Occup Environ Health* 2000;73:150-5.
7. Kahaleh MB, LeRoy EC. Autoimmunity and vascular involvement in systemic sclerosis. *Autoimmunity* 1999;31:195-214.
8. Hausteil UF, Andereg U. Silica induced scleroderma — clinical and experimental aspects. *J Rheumatol* 1998;25:1917-26.

Dural Sinus Thrombosis in Childhood Systemic Lupus Erythematosus

To the Editor:

Neuropsychiatric symptoms occur in up to 75 per cent of patients with systemic lupus erythematosus (SLE), but dural sinus thrombosis (DST) is a rare cause of central nervous system involvement, especially in children^{1,2}. We describe 2 cases of young females with SLE and DST, emphasizing the need for increased awareness of this manifestation.

A 13-year-old female had a generalized tonic-clonic seizure and phenytoin was prescribed. She developed an urticariform rash and phenytoin was substituted by phenobarbital. The cutaneous symptoms persisted and she developed progressive behavioral abnormalities, such as marked aggressiveness and some moments of disorientation, and was then admitted. A typical malar rash with well-characterized photosensitivity was noted and therefore SLE was suspected. No other neurological deficit was found and the rest of the physical examination, including funduscopy, was normal.

There was leukopenia and lymphopenia, but the rest of the blood investigations and the urinary sediment values were normal. Although the sero-

logical test for antinuclear antibody was negative, the patient met the American College of Rheumatology Criteria for SLE — malar rash, photosensitivity, seizure and leukopenia/lymphopenia⁶. The cerebrospinal fluid and a computed tomographic (CT) scan of the brain were normal. She was treated for acute confusional state related to SLE with deflazacort 60 mg, and rapidly improved of all complaints.

Further evaluation showed the lupus anticoagulant (LAC) (thromboplastin and Russell's viper venom time) was negative, the titer of IgG anti-cardiolipin (aCL) was 4.8 GPL (positive if > 20 GPL) and the titer of the IgM aCL was 1.4 MPL (positive if > 20 MPL). Magnetic resonance imaging (MRI) of the brain performed one week after admission revealed an occipital infarct with a central hemorrhage. The magnetic resonance venography (MRV) indicated a filling defect at the left transverse sinus (Figure 1), providing the diagnosis of left transverse sinus thrombosis. The patient was free of complaints and therefore not given anticoagulation. The corticosteroid dose was tapered and she continued to receive anticonvulsant therapy due to a second episode of generalized tonic-clonic seizure 3 months after discharge. She has had no other neurological sequelae, after a followup of 12 months.

A 14-year-old female presented with bilateral knee and ankle arthritis and SLE was diagnosed due to malar rash, lymphopenia and a positive antinuclear antibody⁶. The symptoms improved with low dose deflazacort. Two months after this diagnosis, she was brought to the emergency room with 4-day history of abdominal pain, headache and progressive somnolence with disorientation and momentary loss of consciousness. The pupils were isocoric and photoreactive but a right abducent nerve paresis was observed. The rest of the physical examination was unremarkable.

Blood investigations showed lymphopenia and a positive antinuclear antibody (dilution of 1:1280 with a homogeneous pattern). A CT of the brain showed a hyperdense image at topography of the superior sagittal, rectus and left transverse sinus strongly suggesting the diagnosis of DST. The LAC was negative, the serum titer of IgG aCL was 8.9 GPL and the IgM aCL titer was 11.4 MPL. She was treated with high dose prednisone and heparin initially, followed by longterm warfarin. As she improved, the steroid dose was tapered and 3 months after admission, she has no neurological deficits.

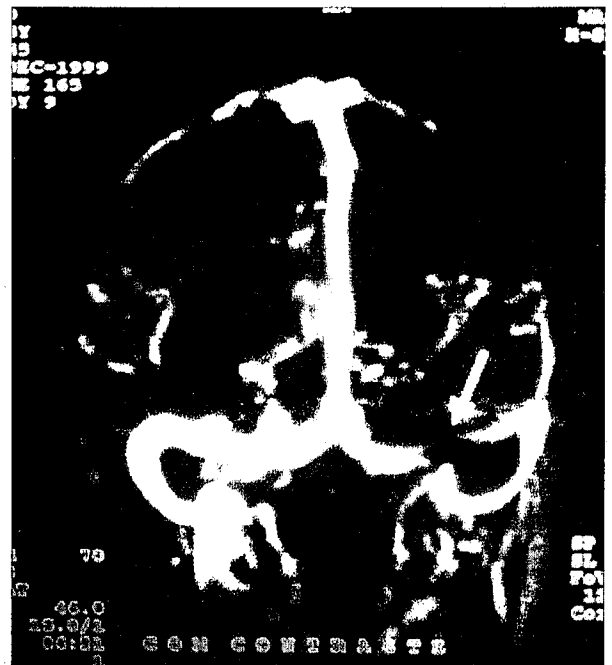

Figure 1. Case 1. The MRV shows a filling defect within the left transverse sinus (arrow), corresponding to the thrombus.

DST is a distinct clinical entity and its association with SLE is well recognized but it has been rarely reported in children^{2,5}. Its pathogenesis has been linked to the presence of antiphospholipid antibodies⁷, but its development is not restricted to SLE patients with antiphospholipid syndrome⁸. In our patients, we found no evidence of either aCL antibodies or the LAC, despite rigorous testing.

The clinical expression of DST varies widely, presenting as headache, seizures, focal neurological deficit, cranial nerve palsy, diffuse encephalopathy or increased intracranial pressure^{5,8}. It is proposed as one of the pathologic mechanisms to SLE-related pseudo tumor cerebri^{3,4}. The confirmation of the diagnosis is achieved by radiological studies⁹. In our second patient, the diagnosis was suggested by a typical CT finding of homogenous hyperdensity in the thrombosed sinuses, which occurs in less than 20% of cases. Other features of DST on CT are a filling defect within the sinus (the empty delta) and a hyperdense cortical vein known as the cord sign. CT also indicates cerebral venous infarction when present, typically bilateral and frequently hemorrhagic. The most common finding on MRI is replacement of the flow void within an affected dural sinus by abnormal signal intensity. In gradient-echo images and MRV, DST is characterized by absence of signal within the dural sinus, as seen in our first patient⁹.

The optimal treatment of DST remains controversial. Published evidence favors anticoagulation therapy with heparin for the acute stage, even when intracerebral hemorrhage is present¹⁰, but there are published reports of patients treated only with steroids who had a favorable outcome⁴. Our first patient was already free of complaints at the time of diagnosis and therefore she was maintained under corticosteroid therapy alone, but most authors suggest the combined therapy of corticosteroid and longterm anticoagulation with warfarin in SLE related DST, which our second patient received^{2,5,8}.

In reported cases, DST has an essentially good longterm prognosis and the majority of patients remain with no neurological sequelae. In a report of SLE related DST, the patients who received early treatment recovered well but due to delayed diagnosis, one patient developed optic atrophy secondary to papilledema².

In summary, DST is a rare clinical manifestation of SLE, especially in children. An increased index of suspicion and radiological investigation provide the diagnosis; and early treatment, combining steroids and anticoagulation, leads to a positive clinical outcome.

BORIS A. CRUZ, MD; LETÍCIA A. SANTOS, MD; REJANE P. DAMASCENO, MD; LUIZ S. RIBEIRO, MD; GILBERTO A. XAVIER JR., MD; SIMONE V. NUNES, MD; GILBERTO B. CAMPOS, MD, PhD; HUMBERTO CRIVELLARI, MD, Hospital Governador Israel Pinheiro, Belo Horizonte, Brazil.

REFERENCES

1. Steinlein MI. Neurologic manifestations of pediatric systemic lupus erythematosus. *Pediatr Neurol* 1995;13:191-7.
2. Vidalket M, Piette JC, Wechsler B, Boussier MG, Brunet P. Cerebral venous thrombosis in systemic lupus erythematosus. *Stroke* 1990;21:1226-31.
3. Kaplan RE, Springate JE, Feld LG, Cohen MF. Pseudo tumor cerebri associated with cerebral venous sinus thrombosis, internal jugular vein thrombosis, and SLE. *J Pediatr* 1985;107:266-8.
4. Parnass SM, Goodwin JA, Patel DV, Levinson DJ, Rheinhard JD. Dural sinus thrombosis: a mechanism for pseudotumor cerebri in systemic lupus erythematosus. *J Rheumatol* 1987;14:152-5.
5. Uziel Y, Laxer RM, Blaser S, Andrew M, Schneider R, Silverman ED. Cerebral vein thrombosis in childhood systemic lupus erythematosus. *J Pediatr* 1995;126:722-7.
6. Tan EM, Cohen AS, Fries JF, et al. 1982 Revised criteria for the classification of systemic lupus erythematosus. *Arthritis Rheum* 1982;25:1271-7.
7. Levine SR, Brey RL. Neurological aspects of antiphospholipid

antibody syndrome. *Lupus* 1996;5:347-53.

8. Flusser D, Abu-Shakra M, Baumgarten-Kleiner A, Flusser G, Sukenik S. Case report: Superior sagittal sinus thrombosis in patient with systemic lupus erythematosus. *Lupus* 1996;5:334-6.
9. Provenzale JM, Joseph GJ, Barboriak DP. Dural sinus thrombosis: Findings on CT and MR Imaging and diagnostic pitfalls. *Am J Roentgenol* 1998;170:777-83.
10. Einhaupl KM, Villringer A, Meister W, et al. Heparin treatment in sinus venous thrombosis. *Lancet* 1991;338:597-600.

Endocarditis in Adult Onset Still's Disease: A 12 Month Followup

To the Editor:

In an earlier letter¹ we described a patient diagnosed with adult onset Still's disease (AOSD) who had a noninfective endocarditis. As described, endocarditis associated with AOSD is unusual^{2,3}. Moreover, no information about the outcome of endocarditis in the setting of AOSD has been reported. We performed a prospective clinical and echocardiographic evaluation of the endocarditis in a patient with AOSD.

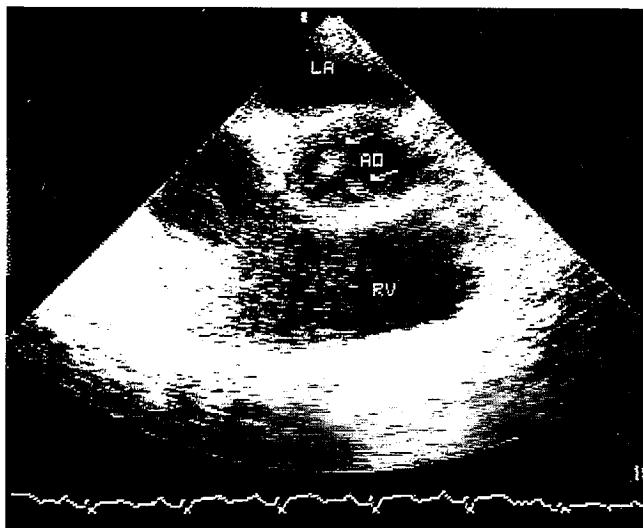
The patient, a 34-year-old woman, had been diagnosed with AOSD a year before, because of synovitis of the wrists and proximal interphalangeal joints of the hands, typical fever peak pattern, urticarial rash with exacerbation during the evening and night, lymphadenopathies, and very high level of serum ferritin¹. At that time a grade 1 systolic cardiac murmur along the lower left sternal border was observed. Color flow Doppler transthoracic echocardiography revealed nodular thickening of the non-coronary and right coronary leaflets of the aortic valve without valve dysfunction. Transesophageal echocardiography confirmed the presence of 2 vegetations in the aortic valve (Figure 1A). Therapy with oral prednisone (0.5 mg/kg/day) and methotrexate (10 mg/week in a single dose) was started, with rapid and complete resolution of symptoms. Prednisone was tapered to complete discontinuation 9 months later. At present, 12 months after diagnosis, the patient remains asymptomatic and the level of serum ferritin is normal, with only 7.5 mg/methotrexate in a single dose every other week. Of note, a recent transthoracic and transesophageal echocardiographic study has also shown regression of the valvular nodular lesions with only minimal thickening of the right coronary leaflet, without valvular dysfunction (Figure 1B).

Heart involvement in AOSD is uncommon^{4,6} and valvular involvement is extremely rare. To date no information about the clinical course of the endocarditis has been described. We emphasize the regression of valvular damage in the setting of AOSD. Treatment for AOSD may be responsible for the regression of the valvular lesions observed in this condition.

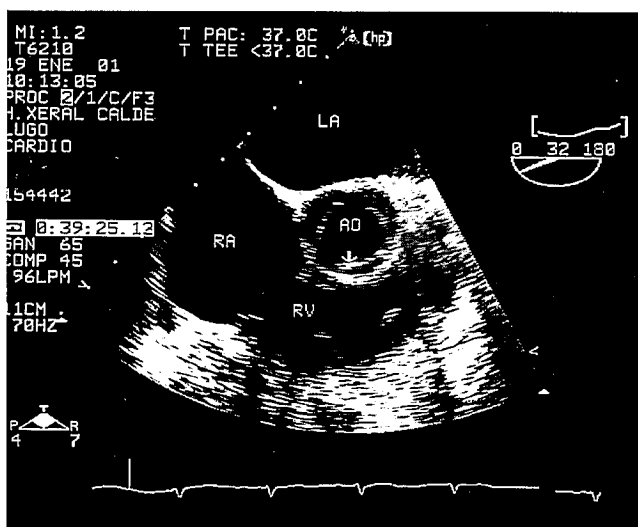
CARLOS GARCÍA-PORRÚA, MD, PhD; CARLOS GONZÁLEZ-JUANATEY, MD; MIGUEL A. GONZÁLEZ-GAY, MD, PhD, Hospital Xeral-Calde, Lugo, Spain.

REFERENCES

1. Holgado S, Olivé A, Casado E, Tena X. Adult onset Still's disease in Catalonia, Spain [letter]. García-Porrúa C, Gonzalez-Gay MA, Crespo F, González-Juanatey C [reply]. *J Rheumatol* 2000; 27:280-1.
2. Taillan B, Fuzibet JG, Vinti H, et al. Non-infectious mitral endocarditis during Still's disease in adults. A case with histologic study of the endocardium. *Ann Med Interne (Paris)* 1990;141:78-9.
3. Zenagui D, De Coninck JP. Atypical presentation of adult Still's disease mimicking acute bacterial endocarditis. *Eur Heart J* 1995;16:1448-50.
4. Pouchot J, Sampalis JS, Beaudet F, et al. Adult Still's disease: manifestations, disease course, and outcome in 62 patients. *Medicine (Baltimore)* 1991;70:118-36.



A



B

Figure 1. A. Transesophageal echocardiography reveals 2 vegetations in the aortic valve. B. After prednisone therapy, lesions are resolved, with no valvular dysfunction.

- Ohta A, Yamaguchi M, Kaneoka H, Nagayoshi T, Hiida M. Adult Still's disease: review of 228 cases from the literature. *J Rheumatol* 1987;14:1139-46.
- Bamberg P, Thomas RJ, Malhotra HS, Kaur U, Bhusnurmath SR, Deodhar SD. Adult onset Still's disease: clinical experience with 18 patients over 15 years in northern India. *Ann Rheum Dis* 1992;51:529-32.

Idiopathic Lateral Sinus Thrombosis Mimicking Giant Cell Arteritis

To the Editor:

Giant cell (temporal) arteritis (GCA) is the most common systemic vasculitis in Western countries¹. Temporal artery biopsy (TAB) is the gold standard test for the diagnosis of GCA². As the pathological lesion is segmental and localized to limited fragments of the artery, the TAB is not always

positive and in most series normal biopsies are described in more than 10% of patients³. Due to this, biopsy-negative patients are classified as having GCA if they fulfill at least 3 of the 1990 American College of Rheumatology (ACR) criteria for the classification of GCA⁴. Knowledge of clues to identify conditions different from GCA that may fulfill some of the clinical features in the 1990 ACR classification criteria is important, as in these cases the management and outcome may differ from GCA⁵. We describe a patient with idiopathic lateral sinus thrombosis who had some clinical features that may be observed in elderly patients with GCA.

A 68-year-old man presented at the emergency room because of recent onset of left hemicranial headache, diplopia, and ptosis of the left eye. On examination his left temporal artery was thickened and swollen, with tenderness to palpation. Left 6th nerve palsy with ptosis and conjunctival chemosis without exophthalmos was observed. The erythrocyte sedimentation rate (ESR) was 85 mm/h. Full blood cell count and coagulation tests were normal. Fibrinogen was 460 mg/dl (normal 170-400). A possible diagnosis of GCA was considered and a TAB was performed. However, although he had some clinical features that may be observed in GCA, pathologic evidence of vasculitis was not confirmed, as the temporal artery biopsy specimen did not show abnormalities. Furthermore, while thickening of temporal artery is generally seen in GCA, the absence of other clinical clues such as jaw claudication or polymyalgia rheumatica, as well as the presence of lateral rectus weakness with ptosis and conjunctival chemosis, raised the suspicion of another condition. Orbital tumors and cerebral sinus thrombosis were considered. Neuroradiological studies, including computed tomography (CT) scan and magnetic resonance imaging (MRI) with MR angiography, were performed. A diagnosis of lateral sinus thrombosis with extension to the cavernous sinus was made (Figure 1). Blood cultures were negative, and dental, ear, nose, and throat examinations were normal. Idiopathic lateral sinus thrombosis was diagnosed. Anticoagulation with heparin was started and the patient was transferred to the neurology division.

Cerebral venous thrombosis is an infrequent condition, which presents a wide spectrum of signs and a highly variable mode of onset⁶. In addition to the classical signs of proptosis, chemosis, and oculomotor paralysis, an isolated 6th nerve palsy and hyperesthesia of the 5th nerve may also be found⁷. In cases like this, appropriate neuroimaging investigation including CT with CT angiography and/or MRI with MR angiography, and if necessary intraarterial angiography, is required⁸.

Our case illustrates the importance of considering other diseases than GCA in elderly patients with a negative TAB who present with cranial man-

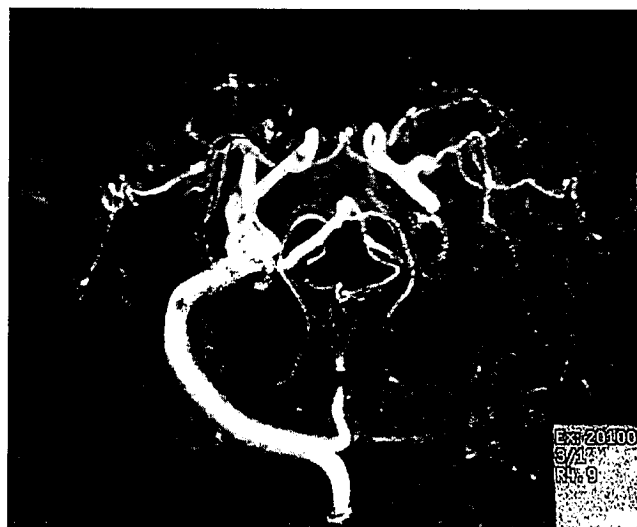

Figure 1. Magnetic resonance angiography showing lateral sinus thrombosis with extension of the process to the cavernous sinus.

ifestations and elevated ESR. In this regard, the 1990 ACR criteria were designed to separate one form of vasculitis from others. Therefore, to use the criteria a diagnosis of vasculitis needs to be made, then the criteria are useful to determine which type of vasculitis is present. Readers should be reminded that those criteria cannot be used appropriately to separate GCA from other types of diseases.

CARLOS GARCÍA-PORRÚA, MD, PhD; JOSE VEGA ANDIÓN, MD;
MIGUEL A. GONZÁLEZ-GAY, MD, PhD, Hospital Xeral-Calde, Lugo,
Spain.

REFERENCES

1. González-Gay MA, García-Porrúa C. Systemic vasculitis in adults in Northwestern Spain, 1988–1997: Clinical and epidemiologic aspects. *Medicine (Baltimore)* 1999;78:292–308.
2. Hall S, Hunder GC. Is temporal artery biopsy prudent? *Mayo Clin Proc* 1984;59:793–6.
3. González-Gay MA, García-Porrúa C, Gonzalez-Louzao C, Rodriguez-Ledo P, Llorca J. Biopsy-negative giant cell arteritis: Clinical spectrum and predictive factors for positive temporal artery biopsy. *Semin Arthritis Rheum* 2001;30:249–56.
4. Hunder GG, Bloch DA, Michel BA, et al. The American College of rheumatology 1990 criteria for the classification of giant cell arteritis. *Arthritis Rheum* 1990;33:1122–8.
5. González-Gay MA, García-Porrúa C, Brañas F. Carotid occlusion mimicking giant cell arteritis. *J Rheumatol* 1998;25:1247–8.
6. Blachere H, Dousset V, Berger O, Series C, Jarnier D, Caille JM. Cerebral panthrombophlebitis in a paucisymptomatic patient. *J Neuroradiol* 1999;26:273–6.
7. Southwick FS, Richardson EP Jr, Swartz MN. Septic thrombosis of the dural venous sinuses. *Medicine (Baltimore)* 1986;65:82–106.
8. Bousser MG. Cerebral venous thrombosis: diagnosis and management. *J Neurol* 2000;247:252–8.

Book Review

Treatment of Rheumatic Diseases. Companion to Kelley's Textbook of Rheumatology

M.H. Weisman, M.E. Weinblatt, J.S. Louie, editors, Philadelphia: W.B. Saunders Company, 2001 604 pages, price \$125.00 US

This hard cover text is written by 66 authors, mainly from the United States with one each from The Netherlands and Canada. The book has 40 chapters divided into 3 sections. The first section describes the differential diagnosis of monoarticular arthritis as well as the diagnosis of acute and chron-

ic polyarthritis. Very useful black and white, as well as colored pictures of the abnormalities that can be found on physical examination enrich this section. Subsequently, there are 8 case descriptions outlining a practical approach to making correct diagnoses in the rheumatic diseases. The third chapter provides information on geriatric rheumatology.

The second section covers, in detail, different rheumatic syndromes. This part of the book is enriched by a chapter about developing medical documentation for rheumatology encounters. One may ask if this particular contribution should not be placed in a separate section and written in a more simplistic way particularly for primary care physicians in order to be used in everyday clinical practice. The last section deals with the therapy of rheumatic diseases. Of particular importance is the description of antirheumatic drugs that can be used during pregnancy and lactation. The chapter on novel therapies for rheumatoid arthritis includes quite exhaustive information about new agents, particularly focusing on interventions that block the effect of proinflammatory cytokines and interventions targeted at cell surface molecules. Once again, the authors give examples of the approach to the management of rheumatoid arthritis, with hypothetical cases.

The treatment of vasculitis provides information about treatment effectiveness from prospective clinical trials as well as information about uncontrolled treatment studies. There is also a table recommending initial therapy for major vasculitic syndromes. This section also describes in detail the management of childhood rheumatic diseases.

In the chapters describing the uses of nonsteroidal antiinflammatory medications, there is up-to-date information regarding nonselective cyclooxygenase inhibitors as well as selective inhibitors of inducible cyclooxygenase.

The chapter on treatment of osteoarthritis provides a suggested protocol for confirmed hand, knee, and hip involvement. The last part of this section provides information about therapy of uncommon rheumatic diseases, as well as infectious agent arthritis and Lyme disease.

The last chapter provides basic information about the effect of rheumatic disorders on bone metabolism (osteoporosis).

All chapters are well organized, and diagrams and photographs enhance many of them.

The second edition of this textbook allows review of the most recent therapies for rheumatic diseases, with examples of practical medical approaches to diagnostic and therapeutic problems in rheumatology. This publication will serve as a good companion to Kelley's *Textbook of Rheumatology* and assist rheumatologists in their everyday clinical practice. In addition, there is much material that can be used to prepare for continuing medical education sessions for our colleagues and general practitioners.

W.P. OLSZYNSKI, MD, PhD, FRCPC, Clinical Professor of Medicine,
University of Saskatchewan, Rheumatology Associates, Saskatoon, SK,
Canada.

Correction

Pata C, Conca K, Yazar A. The role of colchicine in *Helicobacter pylori* prevalence and gastric mucosal changes in Behçet's disease [letter]. *J Rheumatol* 2001;28:1938. Table 1 was omitted from the letter. The letter including Table 1 is reprinted here. We regret the error.

The Role of Colchicine in *Helicobacter pylori* Prevalence and Gastric Mucosal Changes in Behçet's Disease

To the Editor:

Behçet's disease (BD) is prevalent among people living in areas adjacent to the ancient Silk Route. Mucosal ulcerative lesions of the mouth and other regions of the gut are a distinctive feature of the disease¹. Increased leukocyte activity and adhesiveness is another aspect of its physiopathological characteristics² that may relate to the beneficial effects of colchicine as a therapeutic modality³. *Helicobacter pylori* infection, on the other hand, is associated with mucosal lesions of the stomach or duodenum that resemble neutrophilic gastritis microscopically⁴.

We investigated the effects of colchicine on mucosal lesions and on *H. pylori* prevalence among a group of patients with BD. Forty patients (17 men, 23 women, mean age 37.2 ± 6.7 yrs) with dyspeptic complaints, of which 31 were receiving colchicine, classified according to International Study Group criteria⁵ were studied. Forty patients (19 men, 21 women, mean age 37.6 ± 10.6 years) with dyspeptic complaints but without BD were evaluated as controls. All patients referred to the outpatient department with dyspepsia were included in the corresponding groups. A physician guided questionnaire and physical and laboratory examinations were performed for each subject in the study and control groups to determine if another disease might have led to the gastrointestinal lesions. Subjects were also asked about antibiotics, immune modulator, or ulcerogenic medications used in the previous 3 months. All subjects gave informed written consent.

Endoscopic examinations were performed on all subjects and controls using a fiberoptic endoscope (Pentax EG 2940). Duplicate mucosal biopsy specimens from the antrum and corpus of the stomach were obtained from each subject. The results of histopathologic findings were classified in 3 categories as "ulcer," "gastritis," and "normal." *H. pylori* was identified by bedside CLO test⁶ and by microscopic examination of formal/alcohol fixed, paraffin embedded, and hematoxylin-eosin stained specimens.

The mean duration of disease and colchicine therapy was 5.4 and 3.7 years, respectively. The rate of *H. pylori* positive subjects by CLO testing and histologic examination was 72.5%, 82.5% in the BD group and 75%, 77.5% in the control group, respectively ($p > 0.05$). In contrast, the propor-

tion of BD patients with *H. pylori* was significantly associated with colchicine therapy. Specifically, the percentages of *H. pylori* positive patients by CLO test or histological examination were 87.0% and 94.0%, respectively, in the BD group taking colchicine, but 22.0% and 44.0% in the BD group not taking colchicine ($p < 0.05$). Table 1 also shows there is a difference in *H. pylori* infection between the BD group not taking colchicine and control subjects ($p < 0.05$).

Neutrophils have a fundamental role in nonspecific defence against extracellular bacteria⁷. *H. pylori* is an extracellular pathogen that has a particular tropism for the gastric mucosa. Colonization on the gastric mucosa leads to neutrophilic gastritis and peptic ulcer⁸. Colchicine, on the other hand, has well known antimitotic⁹ and suppressive effects on leukocytes¹⁰ that may impair host defence. Whether colchicine also directly causes gastritis-like mucosal lesions is unknown. According to the results of this study, it seems reasonable to consider that Behçet's disease may prevent *H. pylori* colonization, possibly because of increased activity of leukocytes. Colchicine treatment, in contrast, may suppress this beneficial effect and promote more *H. pylori* colonization.

CENGİZ PATA, MD; KAMURAN KONCA, MD; AZİZ YAZAR, MD,
Department of Internal Medicine, Medical School of Mersin University,
İçel, Turkey.

REFERENCES

- Ehrlich GE. Behçet's disease: current concepts. *Compr Ther* 1989;15:27-9.
- Sahin S, Akoglu T, Direskeneli H, Sen LS, Lawrance R. Neutrophil adhesion to endothelial cells and factors affecting adhesion in patients with Behçet's disease. *Ann Rheum Dis* 1996;55:128-33.
- Mangelsdorf HC, White WL, Jorizzo JL. Behçet's disease. Report of twenty-five patients from the United States with prominent mucocutaneous involvement. *J Am Acad Dermatol* 1996;34:745-50.
- Kirchner T, Steininger H, Faller G. Immunopathology of *Helicobacter pylori* gastritis. *Digestion* 1997;58:14-6.
- International Study Group for Behçet's Disease. Criteria for diagnosis of Behçet's disease. *Lancet* 1990;335:1078-80.
- Marshall BJ, Warren JR, Francis GJ. Rapid urease test in the management of the *Campylobacter pyloridis*-associated gastritis. *Am J Gastroenterol* 1987;82:200-10.
- Ryan JL. Bacterial disease. In: Stites DP, Terr AI, Parslow TG, editors. *Medical immunology*. New York: Prentice Hall International; 1997:684-93.
- Kuipers EJ, Thijs JC, Festen HP. The prevalence of *Helicobacter pylori* in peptic ulcer disease. *Aliment Pharmacol Ther* 1995; 9:59-64.
- Ben Chetrit E, Levy M. Colchicine: 1998 update. *Semin Arthritis Rheum* 1998;28:48-9.
- Mantzer Y. Neutrophil function studies in clinical medicine. *Transfus Med Rev* 1987;1:171-81.

Table 1. Prevalence of *Helicobacter pylori* by rapid urease (CLO) test and histopathology in study and control groups.

	Patients with BD								
	Not Taking Colchicine, n = 9			Taking Colchicine, n = 31			Control, n = 40		
	Ulcer	Gastritis	Normal	Ulcer	Gastritis	Normal	Ulcer	Gastritis	Normal
No. of patients (%)	0	5 (56)	4 (44)	4 (13)	25 (81)	2 (6)	7 (18)	24 (60)	9 (23)
CLO+ (%)	0	2 (22)	0	4 (13)	23 (74)	0	6 (15)	21 (53)	3 (8)
Biopsy + (%)	0	4 (44)	0	4 (13)	25 (81)	0	6 (15)	22 (55)	2 (5)

* If the total number (rate) of CLO test and biopsy positive subjects are considered, the statistical difference between the groups taking colchicine and not taking colchicine or control subjects is significant ($p < 0.05$).