Characteristic Macro- and Microscopic Aspect of the Synovial Membrane in Crystal Induced Arthritis

FILIP van den BOSCH, MD; DOMINIQUE BAETEN, MD; ELLI KRUITHOF, MD; FILIP de KEYSER, MD, PhD; ERIC M. VEYS, MD, PhD, Department of Rheumatology, 0K12IB, Ghent University Hospital, Ghent University, De Pintelaan 185, 9000 Ghent, Belgium. Dr. Baeten is a FWO-Vlaanderen Research Assistant. Address reprint requests to Dr. Van den Bosch.

Needle arthroscopy allows easy and safe visualization and sampling of the synovium[1]. Since it is well tolerated and allows therapeutic lavage of the joint[2], it can also be used in relatively benign forms of arthritis such as crystal induced arthritis. We describe the macro- and microscopic aspect of the synovial membrane in 2 cases of crystal induced arthritis.

A 64-year-old woman had bilateral knee synovitis; radiographs showed typical cartilage calcifications confirming chronic pyrophosphate arthritis. Macroscopic inspection at needle arthroscopy revealed white chalky aggregates in the cartilage of the synovium–cartilage junction (Figure 1A). No pyrophosphate crystals were observed in synovial fluid or tissue.

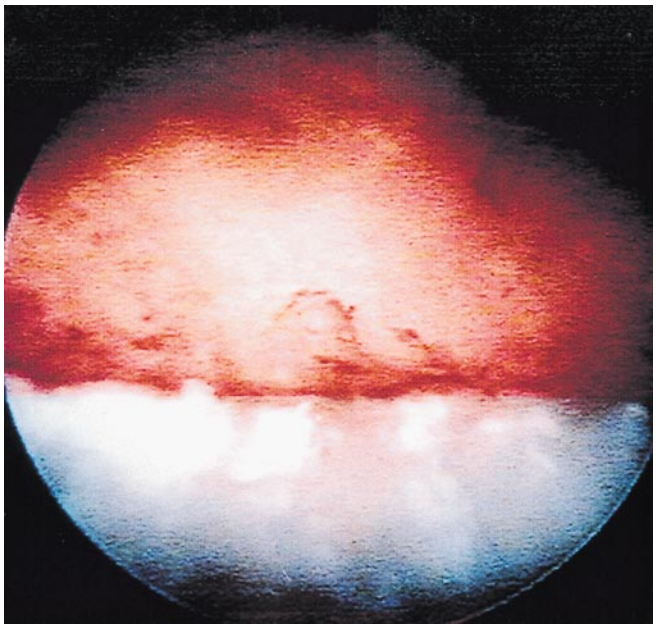

A

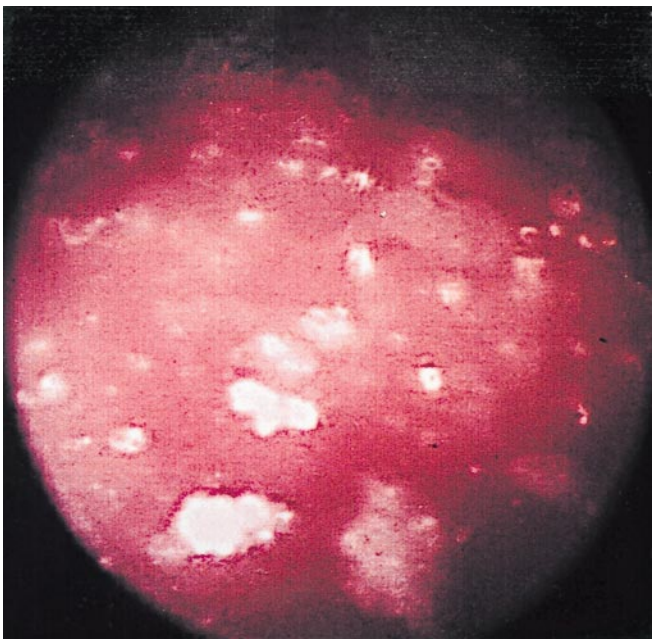

B

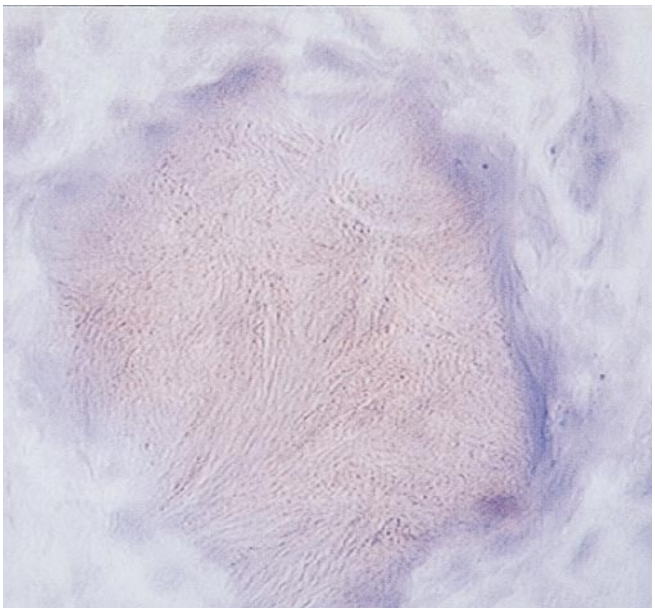

C

Figure 1. A. Chronic calcium pyrophosphate arthritis: macroscopic aspect of the synovium–cartilage junction of the anterior part of the femur, with white chalky deposits in the cartilage and hyperemia of the synovial membrane. B. Gout: macroscopic aspect of the synovial membrane, depicting moderate hyperemia and white crystal deposits. C. Gout: microscopic aspect of the synovium (acetone fixed sections), showing microtophi of urate crystals (magnification ×640).

The second case is a 44-year-old man with inflammatory polysynovitis. Needle arthroscopy allowed macroscopic visualization of crystal deposits in the synovium (Figure 1B). Microscopic analysis of synovial sections fixed in formalin showed inflammatory cells and empty foci surrounded by macrophage-like cells; in contrast, acetone fixed sections revealed sodium urate crystals (Figure 1C), also detected in the synovial fluid, that confirmed the diagnosis of gout. In both cases, lavage had a beneficial therapeutic effect.

Deposition of calcium pyrophosphate crystals usually occurs in cartilage and menisci[3-5]. In contrast, sodium urate crystal deposition mostly occurs in the synovial membrane, sometimes forming microtophi[5]; this can be confirmed microscopically in sections not treated with formalin or other substances dissolving the crystals[3]. The pathognomonic aspects we describe and the possibility of therapeutic lavage make needle arthroscopy a useful tool in difficult cases of crystal induced arthritis.

REFERENCES

1. Baeten D, Van den Bosch F, Elewaut D, Stuer A, Veys EM, De Keyser F. Needle arthroscopy of the knee with synovial biopsy sampling: technical experience in 150 patients. Clin Rheumatol 1999;18:434-41.
2. Sharma A, Baethge BA, Acebes JC, Lisse JR. Arthroscopic lavage treatment in rheumatoid arthritis of the knee. J Rheumatol 1996;23:1872-4.
3. Hanft JR, Kashuk KB, Schabler JA, Segall A. Pseudogout of the ankle: a case study and arthroscopic-assisted treatment. J Foot Surg 1991;30:173-8.
4. Schumacher R. Ultrastructural findings in chondrocalcinosis and pseudogout. Arthritis Rheum 1976;19:413-25.
5. Gravallese EM, Weisman BN, Corson JM, Greene JM. Synovitis of the knee in a 42-year-old man. Arthritis Rheum 1993;36:860-70.