

# Bisphosphonate Associated Osteonecrosis of the Jaw

ALIYA A. KHAN, GEORGE K.B. SÁNDOR, EDWARD DORE, ARCHIBALD D. MORRISON, MAZEN ALSAHLI, FAIZAN AMIN, EDMUND PETERS, DAVID A. HANLEY, SULTAN R. CHAUDRY, BRIAN LENTLE, DAVID W. DEMPSTER, FRANCIS H. GLORIEUX, ALAN J. NEVILLE, REENA M. TALWAR, CAMERON M. CLOKIE, MAJD AL MARDINI, TERRI PAUL, SUNDEEP KHOSLA, ROBERT G. JOSSE, SUSAN SUTHERLAND, DAVID K. LAM, ROBERT P. CARMICHAEL, NICK BLANAS, DAVID KENDLER, STEVEN PETAK, LOUIS GEORGES STE-MARIE, JACQUES BROWN, A. WAYNE EVANS, LORENA RIOS, and JULIET E. COMPSTON

**ABSTRACT.** In 2003, the first reports describing osteonecrosis of the jaw (ONJ) in patients receiving bisphosphonates (BP) were published. These cases occurred in patients with cancer receiving high-dose intravenous BP; however, 5% of the cases were in patients with osteoporosis receiving low-dose bisphosphonate therapy. We present the results of a systematic review of the incidence, risk factors, diagnosis, prevention, and treatment of BP associated ONJ. We conducted a comprehensive literature search for relevant studies on BP associated ONJ in oncology and osteoporosis patients published before February 2008. All selected relevant articles were sorted by area of focus. Data for each area were abstracted by 2 independent reviewers. The results showed that the diagnosis is made clinically. Prospective data evaluating the incidence and etiologic factors are very limited. In oncology patients receiving high-dose intravenous BP, ONJ appears to be dependent on the dose and duration of therapy, with an estimated incidence of 1%–12% at 36 months of exposure. In osteoporosis patients, it is rare, with an estimated incidence < 1 case per 100,000 person-years of exposure. The incidence of ONJ in the general population is not known. Currently, there is insufficient evidence to confirm a causal link between low-dose BP use in the osteoporosis patient population and ONJ. We concluded BP associated ONJ is associated with high-dose BP therapy primarily in the oncology patient population. Prevention and treatment strategies are currently based on expert opinion and focus on maintaining good oral hygiene and conservative surgical intervention. (J Rheumatol 2009;36:478–90; doi:10.3899/jrheum.080759)

## Key Indexing Terms:

OSTEONECROSIS OF THE JAW  
GUIDELINES

BISPHOSPHONATES

SIDE EFFECTS  
EPIDEMIOLOGY

Conducted by The Canadian Taskforce on Osteonecrosis of the Jaw, representing the Canadian Association of Oral and Maxillofacial Surgeons (CAOMS); Canadian Society of Endocrinology and Metabolism (CSEM); Ontario Society of Oral and Maxillofacial Surgeons (OSOMS); Canadian Academy of Oral and Maxillofacial Pathology and Oral Medicine (CAOMPOM); American Association of Clinical Endocrinologists (AACE); International Bone and Mineral Society (IBMS); and International Society for Clinical Densitometry (ISCD).

Supported by the Foundation for Continuing Education and Research of the Canadian Association of Oral and Maxillofacial Surgeons, the Oral and Maxillofacial Surgery Foundation of Canada, and the Calcium Disorders Clinic, St. Joseph's Healthcare, Hamilton, McMaster University, Hamilton, Ontario, Canada.

A.A. Khan, MD, FRCPC, FACP, FACE, Professor of Clinical Medicine, Divisions Endocrinology and Geriatrics, McMaster University, Hamilton, ON, Canada; G.K.B. Sándor, MD, DDS, PhD, FRCDC, FRCSC, FACS, Professor, Head of Oral and Maxillofacial Surgery, Director, Graduate Training Programme in Oral and Maxillofacial Surgery and Anesthesia, University of Toronto, Coordinator of Pediatric Oral and Maxillofacial Surgery, The Hospital for Sick Children and Bloorview Kids Rehabilitation, Toronto, Canada, Professor, Regea Institute for Regenerative Medicine, University of Tampere, Tampere, and Dosent in Oral and Maxillofacial Surgery, University of Oulu, Oulu, Finland; E. Dore, DDS, Oral and Maxillofacial Surgery, Assistant Clinical Professor, Faculty of Health Sciences, McMaster University; A.D. Morrison, DDS,

MSc, FRCDC, Department of Oral and Maxillofacial Sciences, Faculty of Dentistry, Dalhousie University, Halifax, NS, Canada; M. Alsahli, MD, Fellow in Endocrinology, Department of Medicine, Division of Endocrinology and Metabolism, University of Rochester School of Medicine, Rochester, NY, USA; F. Amin, BHSc; E. Peters, DDS, MSc, FRCDC, Professor, Oral Pathology and Oral Medicine, Department of Dentistry, Faculty of Medicine and Dentistry, University of Alberta, Edmonton, AB, Canada; D.A. Hanley, MD, FRCPC, Professor, Departments of Medicine, Community Health Sciences, and Oncology, Division of Endocrinology and Metabolism, University of Calgary Health Sciences Centre, Calgary, AB, Canada; S.R. Chaudhry, BHSc; L. Rios, MD, McMaster University; B. Lentle, MD, Emeritus Professor, University of British Columbia, Vancouver, BC, Canada, Past-President, Canadian Association of Radiology; D.W. Dempster, PhD, Professor of Clinical Pathology, Columbia University, Director, Regional Bone Center, Helen Hayes Hospital, New York, NY, USA; F.H. Glorieux, OC, MD, PhD, Professor of Surgery, Pediatrics, and Human Genetics, McGill University, Director of Research, Genetics Unit, Shriners Hospital for Children, Montreal, QC, Canada; A.J. Neville, MD, MBChB, MEd, Professor, Departments of Oncology and Medicine, Assistant Dean, Undergraduate MD Program, Michael G. DeGroote School of Medicine, McMaster University; R.M. Talwar, DDS, Division of Oral and Maxillofacial Surgery, University of Toronto; C.M. Clokie, DDS, Division of Oral and Maxillofacial Surgery and Anesthesia, Mount Sinai Hospital, University of Toronto; M. Al Mardini, DDS, University of Rochester Eastman Dental

Center; T. Paul, MSc, MD, FRCPC, Assistant Professor, Divisions of Endocrinology and Metabolism, Department of Medicine, Schulich School of Medicine and Dentistry, The University of Western Ontario, London, ON, Canada; S. Khosla, MD, Professor of Medicine, College of Medicine, Mayo Clinic, Rochester, MN, USA; R.G. Josse, BSc, MB, BS, FRCP, FRCPC, FACP, FACE, Medical Director, Osteoporosis Centre, Division of Endocrinology and Metabolism, St. Michael's Hospital, Professor of Medicine, University of Toronto; S. Sutherland, DDS, MSc, FRCDC; D.K. Lam, DDS, Division of Oral and Maxillofacial Surgery and Anesthesia, Mount Sinai Hospital, University of Toronto; R.P. Carmichael, DMD, MSc, FRCDC, Chief of Dentistry, Bloorview Kids Rehabilitation, Coordinator of Prosthodontic, Hospital for Sick Children, Toronto, ON, Canada; N. Blanas, DDS, FRCDC, Women's College Health Sciences Centre and Faculty of Dentistry, Toronto, ON, Canada; D. Kendler, MD, FRCPC, Associate Professor of Medicine, University of British Columbia, Past President, International Society for Clinical Densitometry; S. Petak, MD, JD, Texas Institute for Reproductive Medicine and Endocrinology, Clinical Faculty, University of Texas Medical School at Houston, Houston, TX, USA; L.G. Ste-Marie, MD, CSPQ, Endocrine Service and Centre de recherche du Centre hospitalier de l'Université de Montréal, Montréal, QC, Canada; J. Brown, MD, FRCPC; A.W. Evans, DDS; J.E. Compston, Professor of Bone Medicine, University of Cambridge, Department of Medicine, School of Clinical Medicine and Addenbrooke's NHS Trust, Cambridge, UK.

Address reprint requests to Dr. A. Khan, Divisions of Endocrinology and Geriatrics, McMaster University, 331 Sheddon Avenue, Oakville, ON L6J 1X8. E-mail: avkhan@aol.com

Accepted for publication August 19, 2008.

Osteonecrosis of the jaw (ONJ) is characterized by the accumulation of dead exposed bone in the oral cavity. Over the past century, it has been associated with tissue damage following head and neck irradiation in cancer patients. Other risk factors for the development of osteonecrosis include underlying malignancy, chemotherapy, corticosteroids, and local infection<sup>1-3</sup>. Impaired blood supply appears to be an important risk factor for the development of osteonecrosis. Osteoradionecrosis is believed to result from ionizing radiation damage to the microvasculature and to bone cells in the mandible and maxilla. Osteonecrosis is associated with significant morbidity and can be a difficult condition to treat. In 2003, the first reports describing ONJ in patients receiving bisphosphonates were published. High-dose intravenous (IV) bisphosphonate use in the oncology patient population has been recognized as a contributing factor to the development of ONJ. It is, however, not known if low-dose bisphosphonate use in the osteoporosis population is also associated with osteonecrosis. However, due to concerns regarding a possible link between low-dose bisphosphonate therapy in osteoporosis patients and ONJ, patients receiving bisphosphonates have become increasingly concerned regarding potential oral side effects of these agents.

Bisphosphonates currently serve as a cornerstone in the management of osteoporosis and metabolic bone disease<sup>4</sup> and are also of proven benefit in reducing skeletal complications of malignancy<sup>5-10</sup>. The mechanisms whereby bisphosphonates may contribute to the development of osteonecrosis are still not fully understood. Proposed mechanisms include further reduction in osteoclastic activity in an area of bone that may be relatively hypocellular due to previous chemotherapy and/or radiotherapy impairing the

ability of the bone to resorb and replace damaged tissue. This may explain the impaired bone healing at sites of dental extraction. Aminobisphosphonates have also been postulated to have antiangiogenic effects<sup>11</sup>. However, other agents known to have antiangiogenic effects, such as thalidomide, that are also effective agents in myeloma have not been confirmed as contributing factors to the development of ONJ<sup>12</sup>.

Reid and colleagues recently proposed that bisphosphonates may have toxic effects on oral epithelium overlying areas of high bone bisphosphonate concentrations, decreasing the ability of the oral mucosa to heal following local trauma such as tooth extraction<sup>13</sup>. Data to support this hypothesis come from the case of contact stomatitis in a patient sucking bisphosphonate tablets<sup>14</sup>. To understand the pathogenesis of bisphosphonate associated osteonecrosis further prospective data are needed.

The purpose of this systematic review is to provide an organized summary and analysis of the evidence available on the following key areas pertaining to bisphosphonate associated ONJ: (1) diagnostic features, (2) incidence and prevalence, (3) risk factors, (4) prevention, (5) staging, and (6) treatment. We also aimed to identify current knowledge gaps pertaining to bisphosphonate associated ONJ and propose a research agenda for this condition.

## MATERIALS AND METHODS

This systematic review is the basis for the Canadian Consensus Practice Guidelines for Bisphosphonate Associated Osteonecrosis of the Jaw<sup>15</sup>. The Canadian Association of Oral and Maxillofacial Surgeons in association with national and international multidisciplinary societies formalized the Canadian Task Force on Osteonecrosis of the Jaw in 2006. The multidisciplinary task force included representatives from the relevant societies representing the disciplines of oral surgery, endocrinology, dentistry, oral pathology and oral medicine, rheumatology, and oncology. The task force identified 6 research questions to be addressed by the review: (1) What are the diagnostic features of bisphosphonate associated osteonecrosis of the jaw? (2) How common is bisphosphonate associated osteonecrosis of the jaw? (3) What are the risk factors for bisphosphonate associated osteonecrosis of the jaw? (4) Can we prevent bisphosphonate associated osteonecrosis of the jaw? (5) How do we stage established bisphosphonate associated osteonecrosis of the jaw? (6) What are the current treatment strategies for bisphosphonate associated osteonecrosis of the jaw?

**Study identification.** As the amount of literature on the topic is limited, a wide literature search was utilized. The electronic search was conducted in Medline (1966 to October 2007) and Embase (1980 to October 2007) using OVID. A search strategy was developed for each database by combining medical subject headings and/or text words from 4 categories: interventions (bisphosphonates), population (oncology and osteoporosis), areas of interest for the review (diagnosis, incidence, risk factors, treatment), and outcome (osteonecrosis of the jaw). All searches were limited to human studies published in the English language. The electronic search was updated January 26, 2008. The results of both database searches were combined and duplicate articles were excluded. We also searched the Cochrane Database of systematic reviews. A manual search of the bibliography of key published articles was also performed. In order to obtain additional unpublished data, personal communication with relevant experts was conducted and pharmaceutical companies were invited to submit relevant information. An electronic search of meeting abstracts of the American Society of Clinical Oncology and American Society of Hematology was also conducted.

**Study selection.** The search results were screened independently by 2 reviewers (FA, MA) using the title and abstracts. All the articles considered potentially relevant by either of the two reviewers were evaluated in full text. All original studies evaluating bisphosphonate associated osteonecrosis of the jaw in either the oncology or osteoporosis patient population of any age were included. Reviews and editorials addressing bisphosphonate associated osteonecrosis of the jaw were also included. Studies that were clearly not related to the 6 specific areas of interest were excluded. Study design was not used as a criterion for exclusion due to the paucity of high quality studies. Figure 1 summarizes the study selection process.

**Data synthesis and analysis.** The articles were sorted according to their corresponding key area of focus. Data abstraction was carried out independently by 2 reviewers (F. Amin, M. Alsahli) in duplicate. Disagreements were resolved by consensus, and when consensus could not be reached, by a third adjudicator (A. Khan). Studies were classified by their study design.

## RESULTS

Ninety-two studies were included, consisting of 34 reviews, 18 case series, 16 case reports, 10 editorials, 2 prospective observational studies, 2 surveys, 8 comments and letters to editors, and 2 clinical guidelines.

## DISCUSSION

There are very limited prospective data evaluating the true incidence of and the risk factors contributing to the development of bisphosphonate associated ONJ. The quality of evidence of many of the case reports is poor, and important patient information pertaining to risk factors and diagnosis

was not included in the publication. Evidence regarding risk factors related to the development of ONJ is very weak at this stage and further study is required. The underlying pathogenesis resulting in the development of osteonecrosis with bisphosphonate use is not well defined at this stage. The incidence of osteonecrosis in the general population is currently not known. The incidence is estimated to be 1% to 12% in the oncology patient population receiving high-dose IV bisphosphonates, and appears to be dependent on dose and duration of bisphosphonate therapy. In the osteoporosis population, bisphosphonate associated ONJ is rare, with an estimated incidence of less than 1 case per 100,000 person-years of exposure. Conservative management addressing local infection, pain control, and maintaining adequate nutrition and hydration are advised. These recommendations are based on expert opinion due to the lack of prospective high quality data to guide recommendations for therapy.

### What are the diagnostic features of ONJ associated with bisphosphonate therapy?

We identified 18 case series, 13 case reports, 2 surveys, and 2 clinical guidelines presenting the clinical features of bisphosphonate associated osteonecrosis at the time of diagnosis. The diagnosis is made clinically in the presence of exposed bone in the maxillofacial region for more than 8 weeks in the absence of radiotherapy to the jaw<sup>16</sup>. If the exposed bone has been present for less than 8 weeks, it should be followed to confirm that soft tissues close; such a case would be described as a suspected case of osteonecrosis<sup>16</sup>.

**Clinical characteristics.** As the blood supply to the cortex is derived from the periosteum, the exposed bone is indicative of underlying necrotic bone. Sites of osteonecrosis can become secondarily infected and patients can present with local pain as well as soft tissue swelling and inflammation. The condition can progress to more severe lesions with development of draining fistulas; pathologic fractures may also occur<sup>17</sup>. The clinical diagnosis of osteonecrosis does not require histopathologic evaluation or radiographic features in order to confirm the diagnosis.

**Role of diagnostic imaging in the diagnosis of bisphosphonate associated ONJ.** A retrospective study<sup>18</sup> evaluated the radiographic features of bisphosphonate associated ONJ with dental panoramic radiographs and spiral computerized tomography (CT). Radiographic features may include sclerotic lamina dura around individual teeth, sclerotic bone over the mylohyoid ridge, widened periodontal ligaments, and/or regions of mottled bone in the jaw, most frequently in the molar/premolar regions<sup>19,20</sup>. There are no studies that indicate that these features are specific for the diagnosis of bisphosphonate associated ONJ<sup>20</sup>. ONJ is an imperfectly characterized syndrome, and the radiological findings represent a diverse spectrum.

In radiation induced ONJ, investigators had found few

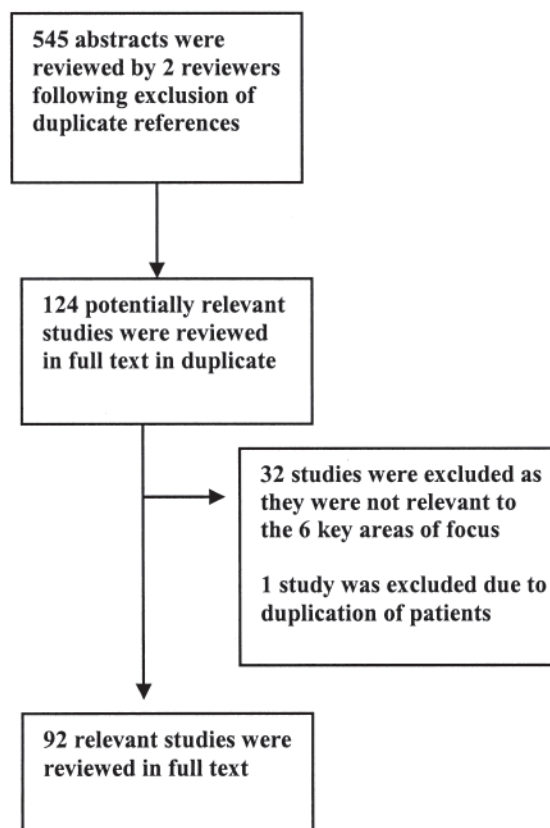


Figure 1. The article selection process.

radiological signs of diagnostic or prognostic value. Epstein, *et al*<sup>21</sup> studied the role of radiographic and nuclear imaging in evaluating postradiotherapy ONJ. Radiographic changes did not correlate with the clinical status of patients. All bone scans were abnormal at the time of diagnosis of osteonecrosis, but remained abnormal irrespective of treatment success or failure. Gallium-67 uptake did not aid in diagnosis, but persisting positive gallium scans seemed to indicate the need for surgery following hyperbaric oxygen therapy<sup>21</sup>.

Bisdasa, *et al*<sup>22</sup> examined 32 patients with suspected bisphosphonate associated ONJ with unenhanced CT and contrast enhanced magnetic resonance imaging (MRI), and correlated their findings with surgical specimens. Osteonecrosis with *Actinomyces* infection was identified in the mandible of 18 patients, in the maxilla of 8 patients, and in both jaws in 6 patients. The CT findings were of mixed osteolytic and sclerotic regions in the jaws with or without periosteal new bone formation. The marrow space in the jaws was reduced. The T1 weighted MRI signal was hypointense in nearly all cases. The gadolinium enhanced MRI images revealed intensity changes in the cortical and subcortical bone structures in all patients. The T2 weighted MRI signal was hypointense on the affected side in 28 of 32 patients. Abnormal gadolinium enhancement was observed in the neighboring soft tissues, in all patients. A local reactive lymphadenopathy was also uniformly present. The authors concluded that bisphosphonate induced ONJ presents a wide variety of CT and MRI features that are readily recognized and help to determine the extent of the disease; however, they are not specific for the disease.

Similar findings have been reported by Phal, *et al*<sup>23</sup>, with the less common addition of poorly or nonhealing extraction sockets, periapical radiolucent areas, widening of the periodontal ligament space, osteolysis, sequestra, oroantral fistulae, soft tissue thickening, and periosteal new bone formation<sup>23</sup>.

In a radiological-pathological correlative study by Bedogni, *et al*, CT scans again showed increased bone density, periosteal reaction, and bony sequestrations in advanced disease<sup>24</sup>. Using MRI, exposed areas were found to have a low signal in T1 and T2 weighted and inversion recovery (IR) images, which suggests low water content, and histopathologically were correlated with acellularity and ischemia. Unexposed diseased bone was characterized by T1 hypointensity and T2 and IR hyperintensity, which suggests high water content and inflammation, associated with hypercellularity, osteogenesis, and hypervascularity resembling osteomyelitis. Thus, diseased bone extended beyond the limits of the bone exposed in the oral cavity. Histopathologic examination correlated well with CT and MRI scans, which are the choice for evaluation of bisphosphonate associated jawbone osteonecrosis, although the findings are not specific.

Since MRI and radionuclide bone scanning are effective

in the early diagnosis of aseptic necrosis of the femoral head, before structural changes result, there was reason to hope that early imaging of the jaws might be productive in ONJ. This has not yet proved to be the case. When the disease is established the radiological findings are variable and nonspecific. The exposed and infected bone is of itself good evidence of ONJ so that for the present, pending some innovative approaches<sup>16</sup>, the best imaging method seems to be inspection with radiological techniques used to examine disease extent and potential complications.

*Role of the histopathological examination.* The histopathologic examination can easily confirm the presence of necrotic bone. A tissue biopsy should be completed if metastatic disease is a potential diagnosis; however, it is not necessary for the clinical diagnosis of ONJ. The criteria for confirming ONJ in the setting of current or previous bisphosphonate use include the presence of exposed necrotic bone in the maxillofacial region for more than 8 weeks in the absence of a history of radiotherapy to the jaw<sup>16</sup>. Of note, this definition does not distinguish between lesions related to high-dose IV bisphosphonates in the oncology patient population and the lower doses given orally or intravenously in the osteoporosis population.

*Differential diagnosis.* An important differential to consider in patients presenting clinically with ONJ is the "spontaneous sequestration" or "lingual mandibular sequestration with ulceration" that resolves spontaneously, which was identified in the pre-bisphosphonate era<sup>25-29</sup>. This is a less aggressive and self-limited pathologic process that develops without any obvious eliciting factor and is characterized by exposed necrotic bone involving the lingual mandible at the level of the mylohyoid ridge. Cases of lingual mandibular sequestration clinically appear similar to mild forms of bisphosphonate associated ONJ<sup>20</sup>. In addition to the similar clinical appearance, lingual mandibular sequestration has a propensity to develop in the posterior/lingual mandible similar to bisphosphonate associated ONJ<sup>26-31</sup>. Lingual mandibular sequestration and ulceration (LMSU) was first described in 1993 and reports of this condition indicate that it spontaneously resolves within a few days up to 12 weeks<sup>25</sup>. None of the patients with lingual mandibular sequestration have been taking bisphosphonates. The histopathologic examination has shown nonvital bone with zones of irregular resorption and associated bacterial masses. It appears, therefore, that there may be an overlap of cases of LMSU and bisphosphonate associated ONJ. The sites for the development of many cases of bisphosphonate associated ONJ are also similar to LMSU, being in the area of the mylohyoid ridge<sup>32</sup>. Further, as with LMSU, bisphosphonate associated ONJ may occur spontaneously without an inciting event in up to 25% of cases<sup>17</sup>.

Necrotic bone in bisphosphonate associated ONJ has been reported to show a paucity of Howship's lacunae and reversal lines. These features are present in zones of bone

Table 1. Reports on cases of osteonecrosis of the jaw.

Study	Patients, n	Bisphosphonate	Previous Dental Procedure, n (%) <sup>*</sup>	Cancer, n (%)	Study Type
Kanat <sup>36</sup>	4	Zoledronic acid (n = 2) Pamidronate & zoledronic acid (n = 2)	3 (75)	4 (100)	ROS
Black <sup>37</sup>	1 (out of 3889 patients)	Zoledronic acid (n = 1)	1 (100)		ROS
Mavrokokki <sup>38</sup>	114	Pamidronate & zoledronic acid (n = 13) Zoledronic acid (n = 43) Pamidronate (n = 20) Alendronate (n = 30) Alendronate & pamidronate (1) Risedronate (n = 2) Clodronate (n = 2) Alendronate & risedronate (n = 2) Zoledronic acid & ibandronate (n = 1)	Not clearly reported	82 (72)	ROS
Bamias <sup>39</sup>	17 out of 252	Pamidronate & zoledronic acid (n = 9 out of 69) Zoledronic acid & ibandronate e (n = 1 out of 15) Zoledronic acid (n = 7 out of 105)	13 (76)	17 (100)	Prospective observational
Dimitrakopoulos <sup>40</sup>	11	Pamidronate & zoledronic acid (n = 4) Zoledronic acid (n = 6) Pamidronate, ibandronate, & zoledronic acid (n = 1)	11 (100)	10 (91)	ROS
Dannemann <sup>41</sup>	14	Pamidronate & zoledronic acid (n = 6) Zoledronic acid (n = 8)	14 (100)	14 (100)	ROS
Salesi <sup>42</sup>	12	Pamidronate & zoledronic acid (n = 1) Zoledronic acid (n = 11)	7 (58)	12 (100)	ROS
Farrugia <sup>43</sup>	23	Pamidronate & zoledronic acid (n = 3) Pamidronate (n = 4) Zoledronic acid (n = 11) Alendronate (n = 5)	9 (39)	18 (78)	ROS
Zarychanski <sup>44</sup>	12	Pamidronate	8 (66)	12 (100)	ROS
Thakkar <sup>45</sup>	17	Pamidronate & zoledronic acid (n = 6) Zoledronic acid (n = 7) Pamidronate (n = 4)	3 (17)	17 (100)	ROS
Bagan <sup>46</sup>	20	Pamidronate & zoledronic acid (n = 6) Zoledronic acid (n = 9) Pamidronate (n = 5)	11 (55)	20 (100)	ROS
Merigo <sup>47</sup>	29	Pamidronate & zoledronic acid (n = 11) Zoledronic acid (n = 15) Alendronate (n = 3)	15 (51)	26 (90)	ROS
Marx <sup>17</sup>	119	Pamidronate & zoledronic acid (n = 36) Zoledronic acid (n = 48) Pamidronate (n = 32) Alendronate (n = 3)	55 (46)	116 (97)	ROS
Migliorati <sup>32</sup>	18	Pamidronate & zoledronic acid (n = 6) Zoledronic acid (n = 8) Pamidronate (n = 3) Alendronate (n = 1)	6 (33)	17 (94)	ROS
Purcell <sup>48</sup>	13	Pamidronate & zoledronic acid (n = 1) Zoledronic acid (n = 8) Pamidronate (n = 3) Alendronate (n = 1)	5 (38)	12 (92)	ROS
Pires <sup>49</sup>		Pamidronate & zoledronic acid (n = 5) Zoledronic acid (n = 3) Pamidronate (n = 4)	8 (67)	12 (100)	ROS
Melo <sup>50</sup>	11	Pamidronate & zoledronic acid (n = 3) Zoledronic acid (n = 4) Pamidronate (n = 4)	9 (82)	11 (100)	ROS
Estilo <sup>51</sup>	13	Intravenous forms, not specified	9 (69)	13 (100)	ROS
Ruggiero <sup>3</sup>	63	Pamidronate & zoledronic acid (n = 13) Zoledronic acid (n = 9) Pamidronate (n = 34) Alendronate & zoledronic acid (n = 1) Alendronate (n = 5) Risedronate (n = 1)	54 (86)	56 (89)	ROS

Table 1. Continued.

Study	Patients, n	Bisphosphonate	Previous Dental Procedure, n (%) <sup>*</sup>	Cancer, n (%)	Study Type
Marx <sup>2</sup>	36	Pamidronate & zoledronic acid (n = 6) Zoledronic acid (n = 6) Pamidronate (n = 24)	28 (77)	35 (97)	ROS
Merigo <sup>52</sup>	4	Zoledronic acid (n = 2) Zoledronic acid & pamidronate (n = 2)	4 (100)	4 (100)	Case series
Sanna <sup>53</sup>	10	Pamidronate Zoledronic acid	4 (40)	4 (100)	Case series
Bagan <sup>54</sup>	10	Zoledronic acid (n = 2) Pamidronate (n = 4) Zoledronic acid & pamidronate (n = 4)	7 (70)	10 (100)	Case series
Lugassy <sup>55</sup>	3	Pamidronate (n = 1) Zoledronic acid & pamidronate (n = 2)	2 (66.6)	3 (100)	Case series
Migliorati <sup>56</sup>	5	Zoledronic acid & pamidronate	NR	NR	Case series
Carter <sup>57</sup>	4	Pamidronate (n = 3) Alendronate (n = 1)	NR	NR	Case series
Wang <sup>58</sup>	3	Pamidronate	3 (100)	3 (100)	Case series
Kademani <sup>59</sup>	2	Zoledronic acid (n = 1) Pamidronate (n = 1)	2 (100)	1 (50)	Case series
Pastor-Zuazaga <sup>60</sup>	3	Zoledronic acid (n = 1) Pamidronate & zoledronic acid (n = 1) Pamidronate (n = 1)	2 (66)	3 (100)	Case series
Hansen <sup>61</sup>	8	Pamidronate & zoledronic acid (n = 6) Ibandronate & zoledronic acid (n = 1) Zoledronic acid (n = 1)	6 (75)	8 (100)	Case series
Carter <sup>62</sup>	5	Pamidronate (n = 4) Alendronate (n = 1)	5 (100)	2 (40)	Case series
Ficarra <sup>63</sup>	9	Zoledronic acid (n = 6) Zoledronic acid & pamidronate (n = 3)	9 (100)	9 (100)	Case series
Katz <sup>64</sup>	3	Zoledronic acid & pamidronate (n = 2) Pamidronate (n = 1)	3 (100)	3 (100)	Case series
Lenz <sup>65</sup>	3	Zoledronic acid (n = 2) Ibandronate (n = 1)	0 (0)	3 (100)	Case series
Durie <sup>66</sup>	1203	Zoledronic acid (n = 642) Pamidronate (n = 262)	NR	1203 (100)	Survey
Zervas <sup>67</sup>	28/254	Zoledronic acid (n = 6 out of 91) Pamidronate (n = 1 out of 78) Zoledronic acid & pamidronate (n = 21 out of 85)	13	303	POS

<sup>\*</sup> In the majority of the studies, this referred to a dental procedure while on bisphosphonate therapy, but this detail was not provided in all reports. ROS: retrospective observational study; POS: prospective observational study; NR: not reported.

resorption<sup>33</sup>. Additionally, the vital bone at the edge of necrotic zones has been found to exhibit enlarged osteoclasts with increased numbers of nuclei. This feature has also been observed in iliac crest bone biopsies from patients with osteoporosis treated with bisphosphonates<sup>34</sup>. Local infection with osteomyelitis can also present with exposed bone, as can periodontal disease, gingivitis, and local malignant lesions. A biopsy is recommended if local malignancy is a clinical consideration.

### How common is bisphosphonate associated ONJ?

In a systematic review of bisphosphonate associated ONJ, Woo, *et al* identified at least 368 cases up to January 2006<sup>35</sup>. Table 1 summarizes the existing reports. Use of high-dose IV bisphosphonate in oncology patients appears to be asso-

ciated with a significantly greater risk of ONJ in comparison to the lower doses used in patients with metabolic bone disease (i.e., osteoporosis or Paget's disease). For this reason, a separate analysis on the incidence of ONJ for each population was performed.

*Incidence of bisphosphonate associated ONJ among cancer patients.* We identified 6 studies assessing the incidence of bisphosphonate associated ONJ in the oncology patient population where it was possible to extract incidence data; a summary is given in Table 2. Estimates for the incidence of bisphosphonate associated ONJ varied substantially among the different studies, the cumulative incidence ranging from 1% to 12% at 36 months. Differences in study design may have contributed to the heterogeneity of these results. In order to evaluate incidence, the ideal study design is the



obtain prospective incidence data with stratification of risk factors for ONJ in osteoporosis patients. This also applies to the pediatric population, as currently being evaluated<sup>76</sup>.

Currently, there are no published incidence data for ONJ in Canada. A survey directed to all registered Ontario oral surgeons is currently in process; the study will provide urgently needed information on estimating the incidence of this condition in Ontario. Results are expected to be available in 2009.

### **What are the risk factors for bisphosphonate associated ONJ?**

Our review identified 7 retrospective studies, 18 case series, 2 case reports, and 2 prospective observational studies describing risk factors for bisphosphonate associated ONJ. However, evaluation of risk factors for ONJ in these studies is limited to descriptive analyses. Therefore, the absolute and relative importance of the risk factors in bisphosphonate associated ONJ remain unknown.

*Risk factors for osteonecrosis of the jaw.* Classical risk factors for development of ONJ include head and neck radiotherapy, periodontal disease, trauma, dental extraction, malignancy, chemotherapy, and glucocorticoid and high-dose IV bisphosphonate therapy. Local dental risk factors include areas of bone in the oral cavity that protrude and are covered by a relatively thin mucosa. These areas include mandibular or palatal tori<sup>1,17,25,77</sup>, exostoses, and the mylohyoid ridge<sup>1,17,25</sup>. In addition, ONJ has been reported to occur twice as often in the mandible in comparison to the maxilla<sup>1</sup>. Other dental risk factors are listed in Table 3. Risk factors for osteonecrosis include systemic conditions that may impede local vascularity (Table 4).

Future studies, including post-hoc regression analysis of the different risk factors reported to date, are needed in order to determine which risk factors are more strongly associated than others in the development of ONJ and bisphosphonate associated ONJ.

*Risk factors for bisphosphonate associated ONJ among oncology patients receiving high-dose IV bisphosphonate therapy.* By definition, all patients with bisphosphonate associated ONJ have been treated with a bisphosphonate. Studies indicate that the risk of ONJ appears to be related to the potency, dose and duration of bisphosphonate therapy<sup>2,3,17,38,39,40,68</sup>. For example, the incidence of ONJ was significantly higher in patients using zoledronic acid alone than in patients treated with other IV bisphosphonates or combinations<sup>16,38,40</sup>. A number of studies indicate that high-dose IV zoledronic acid may be more closely associated with osteonecrosis of the jaw than use of pamidronate, other IV bisphosphonates or combinations<sup>39,48,66,68,83</sup>. The duration of bisphosphonate treatment also appears to affect the risk of ONJ. This is supported by the increase in the cumulative incidence of ONJ over time in studies evaluating the incidence at different points (Table 2). In addition, Bamias

and colleagues, in a prospective cohort of 252 patients with metastatic bone disease, found that the median number of infusions of pamidronate or zoledronic acid were significantly higher (35 infusions) in patients who developed ONJ than in those who did not (15 infusions)<sup>39</sup>.

*Risk factors for bisphosphonate associated ONJ among patients with osteoporosis receiving low-dose bisphosphonate therapy.* The ONJ lesions in this population appear to be less severe and more likely to resolve than those found in the oncology patient population receiving high-dose IV bisphosphonate therapy. In the osteoporosis population, it is not known if the incidence of ONJ differs from that seen in the general population<sup>17,19,84,85</sup>. Hence, it remains unclear whether the lower dose of bisphosphonates used in the management of osteoporosis results in any increase in the risk of ONJ beyond what is observed in the general population. At this time there is insufficient evidence to confirm a causal link between the doses of bisphosphonates used for osteoporosis treatment and ONJ.

### **Can we prevent bisphosphonate associated ONJ?**

Currently, there is insufficient evidence to answer this question. Published data addressing the relationship between suspected risk factors and ONJ are weak. It is not known how those risk factors that have been identified interact, making it difficult to develop prevention strategies. Prospective data will enable the development of evidence based recommendations and stratification of risk. Two guidelines containing recommendations for prevention have been published<sup>86,87</sup>.

### **How do we stage established bisphosphonate associated ONJ?**

There are no published studies addressing staging of bisphosphonate associated ONJ. Although staging criteria have been proposed by a number of experts<sup>1,17,19,32</sup>, these have been based on case studies or case series as there are no randomized clinical trials available to assist in outlining staging criteria or establishing recommendations for management of this condition.

The American Association of Oral and Maxillofacial Surgeons 3-stage criteria for bisphosphonate associated ONJ are based upon patient symptoms and clinical findings<sup>1</sup>. Limitations of this system are that it does not take into account the size of the lesion or any variation that may exist in the number of lesion sites. The proposed treatment strategies do not take into consideration the presence of clinical risk factors affecting the development of ONJ, such as the dose of the bisphosphonate, the presence of mobile segments of bony sequestrum, symptomatic dentition issues within the region of ONJ, or systemic conditions permitting cessation of drug therapy. Although early progress has been made toward developing a useful staging system for ONJ, it is clear that there is a need for controlled clinical studies, in

Table 3. Dental risk factors for osteonecrosis of the jaw (ONJ).

- Clinically and radiographically evident periodontitis<sup>17,38</sup>; severe periodontitis with chronic infection and inflammation of the supporting alveolar bone is a major risk factor for ONJ. This condition may be present in 3%–5% of seventh-decade and older adults who still have teeth<sup>17</sup>
- Tooth extraction: up to 60% of cases of ONJ have been reported in patients having had a recent tooth extraction<sup>1,2,17,35,38,50,66</sup>
- Concomitant or past oral infection<sup>35,48,66,77,78</sup>
- Failing root canal treatment with retained periapical infection<sup>35</sup>
- Trauma caused by removable dentures<sup>2,35,38,77</sup>
- Implant placement, past or current<sup>1,2,17,78</sup>; newly placed implants have a poor healing rate in patients receiving IV bisphosphonates and hence are contraindicated<sup>1</sup>. Previously placed implants may have a higher rate of failure. This warrants further study

Table 4. Systemic and other risk factors for osteonecrosis of the jaw (ONJ).

- Concomitant malignant disease and chemotherapy<sup>1,17,38,66,79</sup>
- Glucocorticoid therapy<sup>1,17,35,66,80</sup>
- Diabetes<sup>1,38,81</sup>
- Advanced age: in review of cases of ONJ in patients with multiple myeloma, there was a 9% increase in the risk of developing ONJ with each decade of life<sup>82</sup>
- Smoking and alcohol need to be evaluated further

order to provide clinicians with appropriate guidelines applicable to clinical practice. One such proposal would include a multifactorial staging system taking into account cumulative dose and duration of therapy (oral vs IV bisphosphonates), the site(s) of the lesion(s), overall size (cm) of the lesion(s), and clinical symptoms. This type of staging criteria then would allow development of a more specific treatment regimen for easy use by clinicians. Until such data are available to allow development of a more useful staging system, the Canadian ONJ Task Force recommends that physicians adopt these recommendations<sup>1</sup>.

### How should we treat established bisphosphonate associated ONJ?

Today, the published recommendations are based solely on expert opinion and anecdotal experience. Conservative treatment approaches have proven to be most effective<sup>1,17,18</sup>. It must be emphasized, in all cases, that management of patients diagnosed with established ONJ should be provided by an appropriate dental specialist, such as an oral and maxillofacial surgeon<sup>17</sup>. The goals of treatment are 3-fold.

(1) To educate and reassure each patient regarding potential ONJ complications; dietary counselling and advice regarding appropriate supplements and/or tube feeding for patients with limited ability to eat due to the oral lesions.

(2) To eliminate discomfort, pain, and secondary infection: baking soda with water or an antimicrobial mouth rinse to clean and irrigate the exposed sites is advised. Microbiological culture for secondary infection has been suggested<sup>35</sup>. Treatment for ONJ stage 2 or higher should focus on pain control and on preventing the progression of exposed bone. Recommendations include a 3-week course of penicillin V potassium (Pen V-K) with the addition of metron-

idazole as necessary, in addition to 0.12% chlorhexidine mouth rinse. Clindamycin, doxycycline, and erythromycin also have been used in patients who are allergic to penicillin<sup>1</sup>.

(3) To attempt to arrest the progression of bone exposure: for this purpose it is recommended that one eliminate sharp and ragged bone surfaces with surgical debridement, thereby minimizing trauma to adjacent soft tissues. Mobile or readily identifiable sequestrae should be removed, so that uninvolved bone is not exposed. Extraction of symptomatic teeth in the necrotic zone is not believed to exacerbate established ONJ. Aggressive debridement otherwise is contraindicated. Segmental resection may be required to remove large portions of necrotic or pathologically fractured bone, along with immediate reconstruction using a reconstruction plate. Bone grafting may be problematic, due to potential bone necrosis at the recipient site. Protecting the site by means of a removable prosthesis has also been suggested<sup>88</sup>. Biopsy is advised only if metastasis is suspected. There are limited data regarding the value of hyperbaric oxygen therapy in the management of bisphosphonate associated ONJ<sup>89–94</sup>. This treatment modality may be of benefit in achieving regrowth of oral mucosa over previously exposed bone; however, this requires further prospective study. Interruption of bisphosphonate therapy has also been suggested<sup>1</sup>. Discontinuation of IV bisphosphonate therapy in cancer patients with ONJ has been associated with healing in case reports, suggesting that resolution of ONJ in these patients may be accelerated by cessation of bisphosphonate therapy<sup>95</sup>. In a recent review of 60 cases of ONJ, 7 patients demonstrated improved outcomes with cessation of bisphosphonate therapy over at least 6 months<sup>89</sup>. As current data are insufficient to support or refute this recommenda-

tion, any decision regarding interruption of bisphosphonate therapy (IV or oral) should be made in consultation with the treating oncologist or physician.

### Future directions for research

Prospective data are urgently needed for the development of a comprehensive understanding of the pathophysiology of bisphosphonate associated ONJ. It is also necessary to improve our knowledge of the incidence of ONJ in the general population, as well as in the population exposed to both low- and high-dose bisphosphonate therapy. The effects of longterm administration of high-dose bisphosphonates require further study in the oncology population, with review of current guidelines addressing bisphosphonate use in the oncology population. Prospective data will enable stratification of the risk factors leading to osteonecrosis, and enable a more accurate assessment of prognosis. New imaging modalities may be of value in identifying the condition early, allowing targeted intervention, and this requires further study.

Diagnostic coding specifically indicating ONJ with sub-codes for users and nonusers of bisphosphonates is recommended. This would be of great value in improving the recording of this condition in healthcare databases, allowing further analysis of incidence, risk factors, and prognosis. A registry of all new cases in Canada is recommended and is being planned by the Canadian task force on bisphosphonate associated ONJ. International collaboration with a standardized and unified approach to research is necessary for the development of a successful diagnostic and management strategy for this uncommon condition.

### Conclusions

This systematic review indicates that high-dose IV bisphosphonate use in the oncology population is associated with an increased risk of osteonecrosis that appears to be dependent on dose and duration of therapy. A similar link has not been confirmed with lower-dose bisphosphonate therapy in the osteoporosis population. The incidence of ONJ in the general population is not known. ONJ can occur in the absence of bisphosphonates or other important risk factors such as radiotherapy, chemotherapy, and glucocorticoid use. In these circumstances, ONJ appears to resolve spontaneously and appears to be a benign process. Further studies are needed to fully understand the pathogenesis and incidence of bisphosphonate associated ONJ. The agreed-upon definition of bisphosphonate associated ONJ for both suspected and confirmed cases will be of value in improving the homogeneity of future studies. Current management strategies include addressing pain control and local infection, and maintaining hydration and adequate nutrition. Conservative management of oral lesions is recommended, with surgery being limited to removal of loose sequestra, smoothing of rough bone edges, and removal of necrotic debris. Further

research will build on current knowledge and enable the development of more sophisticated and effective management plans.

### REFERENCES

1. Advisory Task Force on Bisphosphonate-Related Osteonecrosis of the Jaws. American Association of Oral and Maxillofacial Surgeons position paper on bisphosphonate-related osteonecrosis of the jaws. *J Oral Maxillofac Surg* 2007;65:369-76.
2. Marx RE. Pamidronate (Aredia) and zoledronate (Zometa) induced avascular necrosis of the jaws: A growing epidemic. *J Oral Maxillofac Surg* 2003;61:1115-7.
3. Ruggiero SL, Mehrotra B, Rosenberg TJ, et al. Osteonecrosis of the jaws associated with the use of bisphosphonates: a review of 63 cases. *J Oral Maxillofac Surg* 2004;62:527-34.
4. Brown JP, Josse RG. Scientific Advisory Council of the Osteoporosis Society of Canada: 2002 clinical practice guidelines for the diagnosis and management of osteoporosis in Canada. *Can Med Assoc J* 2002;167 Suppl:S1-S34.
5. Berenson JR, Hillner BE, Kyle RA, et al. American Society of Clinical Oncology clinical practice guidelines: the role of bisphosphonates in multiple myeloma. *J Clin Oncol* 2002;20:19-36.
6. Berry S, Waldron T, Winquist E, et al. The use of bisphosphonates in men with hormone-refractory prostate cancer. Practice Guideline Report no. 3-14. Program in Evidence-Based Care; a Cancer Care Ontario Program. January 10, 2005. Toronto: Ontario Ministry of Health and Long-term Care; 2005
7. Berry S, Waldron T, Winquist E, et al. The use of bisphosphonates in men with hormone-refractory prostate cancer: a systematic review of randomized trials. *Can J Urol* 2006;13:3180-8.
8. Hillner BE, Ingle JN, Chlebowski RT, et al. American Society of Clinical Oncology 2003 update on the role of bisphosphonates and bone health issues in women with breast cancer. *J Clin Oncol* 2003;21:4042-57.
9. Kyle RA, Yee GC, Somerfield MR, et al. American Society of Clinical Oncology 2007 clinical practice guideline update on the role of bisphosphonates in multiple myeloma. *J Clin Oncol* 2007;25:2464-72.
10. Saad F, Gleason DM, Murray R, et al. A randomized, placebo-controlled trial of zoledronic acid in patients with hormone-refractory metastatic prostate carcinoma. *J Natl Cancer Inst* 2002;94:1458-68.
11. Santini D, Vincenzi B, Dicuonzo G, et al. Zoledronic acid induces significant and long lasting modifications of circulating angiogenic factors in cancer patients. *Clin Cancer Res* 2003;9:2893-9.
12. Bamias A, Dimopoulos MA. Thalidomide and immunomodulatory drugs in the treatment of cancer. *Exp Opin Invest Drugs* 2005;14:45-55.
13. Reid IR, Bolland MJ, Grey AB. Is bisphosphonate-associated osteonecrosis of the jaw caused by soft tissue toxicity? *Bone* 2007;41:318-20.
14. Rubegni P, Fimiani M. Bisphosphonate-associated contact stomatitis. *New Engl J Med* 2006;355:E25.
15. Khan AA, Sandor GKB, Dore E, et al. Canadian consensus practice guidelines for bisphosphonate associated osteonecrosis of the jaw. *J Rheumatol* 2008;35:1391-7.
16. Khosla S, Burr D, Cauley J, et al. Bisphosphonate-associated osteonecrosis of the jaw: report of a task force of the American Society for Bone and Mineral Research. *J Bone Miner Res* 2007;22:1479-91.
17. Marx RE, Sawatari Y, Fortin M, Broumand V. Bisphosphonate-induced exposed bone (osteonecrosis/osteopetrosis) of the jaws: risk factors, recognition,

## Appendix1. Search strategy

### Search Strategy on Embase 1980- January2008 (Ovid)

# Searches	Terms
1	jaw necrosis/ or exp jaw osteonecrosis/ or osteonecrosis of the jaw.mp/ or jaw disease
2	exp Zoledronic Acid/ or exp Pamidronic Acid/ exp Alendronic Acid/ or exp Risedronic Acid/ or Bisphosphonic Acid Derivative/
3	exp Bone Metastasis/ exp Multiple Myeloma/ Cancer/ or skeletal cancer.mp. exp Breast Cancer/ Prostate Cancer/ Lung Cancer/ Hypercalcemia/ or Malignant Neoplastic Disease/
4	exp OSTEOPOROSIS/ or osteoporosis.mp.
5	Therapy/ or Diagnosis/ or exp Risk Factors/ or Incidence/ or Prevalence/Staging/
6	2 or 3 or 4 or 5
7	1 and 6
8	limit 7 to (human and English language)

### Search strategy on Medline 1966- January 2008 (Ovid)

# Searches	Terms
1	Jaw Diseases/ or Osteonecrosis/ or osteonecrosis of the jaw.mp.
2	zoledronic acid.mp./or pamidronate.mp./ or exp diphosphonates/ or alendronate/ or risedronate.mp./
3	Multiple Myeloma/ or Breast Neoplasms/ or Prostatic Neoplasms/ or cancer skeletal.mp. or Lung Neoplasms/
4	Osteoporosis, Postmenopausal/ or exp Osteoporosis/
5	Therapeutics/ or Diagnosis/ or exp Risk Factors/ or Incidence/ or Prevalence/staging.mp.
6	2 or 3 or 4 or 5
7	1 and 6
8	limit 13 to (english language and humans)

- prevention, and treatment. J Oral Maxillofac Surg 2005;63:1567-75.
18. Bianchi SD, Scoletta M, Cassione FB, et al. Computerized tomographic findings in bisphosphonate-associated osteonecrosis of the jaw in patients with cancer. Oral Surg Oral Med Oral Pathol Oral Radiol Endod 2007;104:249-58.
  19. Ruggiero SL, Fantasia J, Carlson E. Bisphosphonate-related osteonecrosis of the jaw: background and guidelines for diagnosis, staging and management. Oral Surg Oral Med Oral Pathol Oral Radiol Endod 2006;102:433-41.
  20. Pharoah M. Maxillofacial Radiology, University of Toronto. Personal communication. 2007.
  21. Epstein JB, Wong FL, Dickens A, Szasz I, Lepawsky M. Bone and gallium scans in postradiotherapy osteonecrosis of the jaw. Head Neck 1992;14:288-92.
  22. Bisdasa S, Chambron Pinhob N, Smolarzb A, Saderb R, Vogla TJ, Macka MG. Biphosphonate-induced osteonecrosis of the jaws: CT and MRI spectrum of findings in 32 patients. Clin Radiol

- 2008;63:71-7.
23. Phal PM, Myall RW, Assael LA, Weissman JL. Imaging findings of bisphosphonate-associated osteonecrosis of the jaws. *Am J Neuroradiol* 2007;28:1139-45.
24. Bedogni A, Blandamura S, Lokmic Z, et al. Bisphosphonate-associated jawbone osteonecrosis: a correlation between imaging techniques and histopathology. *Oral Surg Oral Med Oral Pathol Oral Radiol Endod* 2008;105:358-64.
25. Peters E, Lovas GL, Wysocki GP. Lingual mandibular sequestration and ulceration. *Oral Surg Oral Med Oral Pathol* 1993;75:739-43.
26. Peters E, Daley T; American Academy of Oral and Maxillofacial Pathology. Persistent painful ulcer of the posterior lingual mandibular mucosa. *J Contemp Dent Pract* 2003;4:71-5.
27. Farah CS, Savage NW. Oral ulceration with bone sequestration. *Aust Dent J* 2003;48:61-4.
28. Kessler HP. Oral and maxillofacial pathology case of the month. Lingual mandibular sequestration with ulceration. *Tex Dent J* 2005;122:198-9, 206-7.
29. Neville HP, Damm DD, Allen CM, et al. Spontaneous sequestration (traumatic sequestration). *Oral and maxillofacial pathology*. Philadelphia: W.B. Saunders Co.; 2002:276-7.
30. Sculley C. Oral ulceration: a new and unusual complication. *Br Dent J* 2002;192:139-40.
31. Sonnier KE, Horning GM. Spontaneous bony exposure: a report of 4 cases of idiopathic exposure and sequestration of alveolar bone. *J Periodontol* 1997;68:758-62.
32. Migliorati CA, Schubert MM, Peterson DE, Seneda LM. Bisphosphonate-associated osteonecrosis of mandibular and maxillary bone: an emerging oral complication of supportive cancer therapy. *Cancer* 2005;104:83-93.
33. Hellstein JW, Marek CL. Bisphosphonate osteochemonecrosis (bis-phossy jaw): Is this phossy jaw of the 21st century? *J Oral Maxillofac Surg* 2005;63:682-9.
34. Dempster DW, Zhou H, Nieves JW, et al. Unusual osteoclast morphology in teriparatide-treated patients who have been pretreated with alendronate [abstract]. *J Bone Miner Res* 2007;22 Suppl 1:S29.
35. Woo SB, Hellstein JW, Kalmar JR. Systematic review: bisphosphonates and osteonecrosis of the jaws. *Ann Intern Med* 2006;144:753-61.
36. Kanat O, Ozet A, Ataergin S, et al. Bisphosphonate treatment as a cause of jaw osteonecrosis. *Oral Dis* 2007;13:346-7.
37. Black DM, Delmas PD, Eastell R, et al. Once-yearly zoledronic acid for treatment of postmenopausal osteoporosis. *N Engl J Med* 2007;356:1809-22.
38. Mavrokokki T, Cheng A, Stein B, Goss A. Nature and frequency of bisphosphonate-associated osteonecrosis of the jaws in Australia. *J Oral Maxillofac Surg* 2007;65:415-23.
39. Bamias A, Kastritis E, Bamia C, et al. Osteonecrosis of the jaw in cancer after treatment with bisphosphonates: incidence and risk factors. *J Clin Oncol* 2005;23:8580-7.
40. Dimitrakopoulos I, Magopoulos C, Karakasis D. Bisphosphonate-induced avascular osteonecrosis of the jaws: a clinical report of 11 cases. *Int J Oral Maxillofac Surg* 2006;35:588-93.
41. Dannemann C, Zwahlen R, Gratz KW. Clinical experiences with bisphosphonate-induced osteochemonecrosis of the jaws. *Swiss Med Wkly* 2006;136:504-9.
42. Salesi N, Pistilli R, Marcelli V, et al. Bisphosphonates and oral cavity avascular bone necrosis: a review of twelve cases. *Anticancer Res* 2006;26:3111-5.
43. Farrugia MC, Summerlin DJ, Krowiak E, et al. Osteonecrosis of the mandible or maxilla associated with the use of new generation bisphosphonates. *Laryngoscope* 2006;116:115-20.
44. Zarychanski R, Elphée E, Walton P, Johnston J. Osteonecrosis of the jaw associated with pamidronate therapy. *Am J Hematol* 2006;81:73-5.
45. Thakkar SG, Isada C, Smith J, et al. Jaw complications associated with bisphosphonate use in patients with plasma cell dyscrasias. *Med Oncol* 2006;23:51-6.
46. Bagan JV, Jimenez Y, Murillo J, et al. Jaw osteonecrosis associated with bisphosphonates: multiple exposed areas and its relationship to teeth extractions. Study of 20 cases. *Oral Oncol* 2006;42:327-9.
47. Merigo E, Manfredi M, Meleti M, et al. Bone necrosis of the jaws associated with bisphosphonate treatment: a report of twenty-nine cases. *Acta Biomed* 2006;77:109-17.
48. Purcell P, Boyd IW. Bisphosphonates and osteonecrosis of the jaw. *Med J Austral* 2005;182:417-8.
49. Pires FR, Miranda A, Cardoso ES, et al. Oral avascular bone necrosis associated with chemotherapy and bisphosphonate therapy. *Oral Dis* 2005;11:365-9.
50. Melo M, Obeid G. Osteonecrosis of the maxilla in a patient with a history of bisphosphonate therapy. *J Can Dent Assoc* 2005;71:111-3.
51. Estilo CS, Van Poznak CH, Williams T, et al. Osteonecrosis of the maxilla and mandible in patients treated with bisphosphonates: a retrospective study. *Proc Am Soc Clin Oncol* 2004;22:1479-91.
52. Merigo E, Manfredi M, Meleti M, et al. Jaw bone necrosis without previous dental extractions associated with the use of bisphosphonates (pamidronate and zoledronate): a four-case report. *J Oral Pathol Med* 2005;34:613-7.
53. Sanna G, Zampino MG, Pelosi G, et al. Jaw avascular bone necrosis associated with long-term use of bisphosphonates. *Ann Oncol* 2005;16:1207-8.
54. Bagan JV, Murillo J, Jimenez Y, et al. Avascular jaw osteonecrosis in association with cancer chemotherapy: series of 10 cases. *J Oral Pathol Med* 2005;34:120-3.
55. Lugassy G, Shaham R, Nemets A, et al. Severe osteomyelitis of the jaw in long-term survivors of multiple myeloma: a new clinical entity. *Am J Med* 2004;117:440-1.
56. Migliorati CA. Bisphosphonates and oral cavity avascular bone necrosis. *J Clin Oncol* 2003;21:4253-4.
57. Carter GD, Goss AN. Bisphosphonates and avascular necrosis of the jaws [letter]. *Aust Dent J* 2003;48:268.
58. Wang J, Goodger NM, Pogrel MA. Osteonecrosis of the jaws associated with cancer chemotherapy. *J Oral Maxillofac Surg* 2003;61:1104-7.
59. Kademani D, Koka S, Lacy MQ, Rajkumar SV. Primary surgical therapy for osteonecrosis of the jaw secondary to bisphosphonate therapy. *Mayo Clin Proc* 2006;81:1100-3.
60. Pastor-Zuazaga D, Garatea-Crelgo J, Martino-Gorbea R, Etayo-Perez A, Sebastian-Lopez C. Osteonecrosis of the jaws and bisphosphonates. Report of three cases. *Med Oral Patol Oral Cir Bucal* 2006;11:E76-9.
61. Hansen T, Kunkel M, Weber A, James Kirkpatrick C. Osteonecrosis of the jaws in patients treated with bisphosphonates — histomorphologic analysis in comparison with infected osteoradionecrosis. *J Oral Pathol Med* 2006;35:155-60.
62. Carter G, Goss AN, Doecke C. Bisphosphonates and avascular necrosis of the jaw: a possible association. *Med J Aust* 2005;182:413-5.
63. Ficarra G, Beninati F, Rubino I, et al. Osteonecrosis of the jaws in periodontal patients with a history of bisphosphonates treatment. *J Clin Periodontol* 2005;32:1123-8.
64. Katz H. Endodontic implications of bisphosphonate-associated osteonecrosis of the jaws: a report of three cases. *J Endod* 2005;31:831-4.
65. Lenz JH, Steiner-Krammer B, Schmidt W, et al. Does avascular necrosis of the jaws in cancer patients only occur following treatment with bisphosphonates? *J Craniomaxillofac Surg*

- 2005;33:395-403.
66. Durie BG, Katz M, Crowley J. Osteonecrosis of the jaws and bisphosphonates. *N Engl J Med* 2005;353:99-102.
67. Zervas K, Verrou E, Teleioudis Z, et al. Incidence, risk factors and management of osteonecrosis of the jaw in patients with multiple myeloma: a single-centre experience in 303 patients. *Br J Haematol* 2006;134:620-3.
68. Dimopoulos MA, Kastritis E, Anagnostopoulos A, et al. Osteonecrosis of the jaw in patients with multiple myeloma treated with bisphosphonates: Evidence of increased risk after treatment with zoledronic acid. *Haematologica* 2006;91:968-71.
69. Tosi P, Zamagni E, Cangini D. Bisphosphonates and osteonecrosis of the jaws: Incidence in a homogeneous series of patients with newly diagnosed multiple myeloma treated with zoledronic acid. *Blood* 2005;106:3467a.
70. Cafrò AM, Barbarano LA, Andriani A. Osteonecrosis of the jaw associated with chronic bisphosphonates therapy: An Italian experience [abstract 5152]. American Society of Hematology Annual Meeting, 2005.
71. Pozzi S, Marcheselli R, Sacchi S. Analysis of frequency and risk factors for developing bisphosphonate associated necrosis of the jaw [abstract 5057]. American Society of Hematology Annual Meeting, 2005.
72. Favus MJ. Diabetes and the risk of osteonecrosis of the jaw [editorial]. *J Clin Endocrinol Metab* 2007;92:817-8.
73. Felsenberg D, Hoffmeister B, Ameling M. Bisphosphonattherapie assoziierte. Kiefernekrosen *Deutsches Arzteblatt* 2008; [abstract; in press].
74. Alendronate sodium. Merck & Co., Inc. 1995-2008. Internet. Available from: [www.fosamax.com](http://www.fosamax.com). Accessed Oct 23 2008.
75. Risedronate sodium. Procter & Gamble Pharmaceuticals. 2008. Internet. Available from: [www.actonel.com](http://www.actonel.com). Accessed Oct 23 2008.
76. Chahine C, Cheung MS, Head TW, Schwartz S, Glorieux FH, Rauch F. Tooth extraction socket healing in pediatric patients treated with intravenous pamidronate. *J Pediatr* 2008;153:719-20.
77. Kademani D, Koka S, Lacy MQ, Rajkumar SV. Primary surgical therapy for osteonecrosis of the jaw secondary to bisphosphonate therapy. *Mayo Clin Proc* 2006;81:1100-3.
78. Hoff AO, Toth BB, Altundag K, et al. Osteonecrosis of the jaw in patients receiving intravenous bisphosphonate therapy [abstract]. ASCO Annual Meeting Proceedings. *J Clin Oncol* 2006;24:8528.
79. Starck WJ, Epker BN. Failure of osseointegrated dental implants after diphosphonate therapy for osteoporosis: a case report. *Int J Oral Maxillofac Implants* 1995;10:74-8.
80. Marx RE. Oral and intravenous bisphosphonate-induced osteonecrosis of the jaws — history, etiology, prevention and treatment. Hanover Park, IL: Quintessence Publishing Co.; 2007.
81. Khamaisi M, Regev E, Yarom N, et al. Possible association between diabetes and bisphosphonate-related jaw osteonecrosis. *J Clin Endocrinol Metab* 2007;92:1172-5.
82. Badros A, Weikel D, Salama A, et al. Osteonecrosis of the jaw in multiple myeloma patients: clinical features and risk factors. *J Clin Oncol* 2006;24:945-52.
83. Zavras AI, Zhu S. Bisphosphonates are associated with increased risk for jaw surgery in medical claims data: Is it osteonecrosis? *J Oral Maxillofac Surg* 2006;64:917-23.
84. Erdogan O, Esen E, Ustun Y. Bony palatal necrosis in a diabetic patient secondary to palatal rotational flap. *J Diabet Complicat* 2005;19:364-7.
85. Herrod NW. Bisphosphonate-associated osteonecrosis. *J Am Dent Assoc* 2006;137:441-3.
86. Melo M, Obeid G. Osteonecrosis of the jaws in patients with a history of receiving bisphosphonate therapy. Strategies for prevention and early recognition. *J Am Dent Assoc* 2005;136:1675-81.
87. Ruggiero S, Gralow J, Marx RE, et al. Practical guidelines for the prevention, diagnosis, and treatment of osteonecrosis of the jaw in patients with cancer. *J Oncol Pract* 2006;2:7-14.
88. Migliorati CA, Casiglia J, Epstein J, et al. Managing the care of patients with bisphosphonate-associated osteonecrosis: an American Academy of Oral Medicine position paper. *J Am Dent Assoc* 2005;136:1658-68.
89. Magopoulos C, Karakinaris G, Telioudis Z, et al. Osteonecrosis of the jaws due to bisphosphonate use. A review of 60 cases and treatment proposals. *Am J Otolaryngol* 2007;28:158-63.
90. Biasotto M, Chiandussi S, Dore F, et al. Clinical aspects and management of bisphosphonates-associated osteonecrosis of the jaws. *Acta Odontol Scand* 2006;64:348-54.
91. Freiburger JJ, Padilla-Burgos R, Chhoeu AH, et al. Hyperbaric oxygen treatment and bisphosphonate-induced osteonecrosis of the jaw: a case series. *J Oral Maxillofac Surg* 2007;65:1321-7.
92. Landesberg R, Wilson T, Grbic JT. Bisphosphonate-associated osteonecrosis of the jaw: conclusions based on an analysis of case series. *Dent Today* 2006;25:52, 54-7.
93. Nastro E, Musolino C, Allegra A, et al. Bisphosphonate-associated osteonecrosis of the jaw in patients with multiple myeloma and breast cancer. *Acta Haematol* 2007;117:181-7.
94. Shimura K, Shimazaki C, Taniguchi K, et al. Hyperbaric oxygen in addition to antibiotic therapy is effective for bisphosphonate-induced osteonecrosis of the jaw in a patient with multiple myeloma. *Int J Hematol* 2006;84:343-5.
95. Treister N, Woo SB. Bisphosphonate-associated osteonecrosis of the jaw. *N Engl J Med* 2006;355:2348-52.